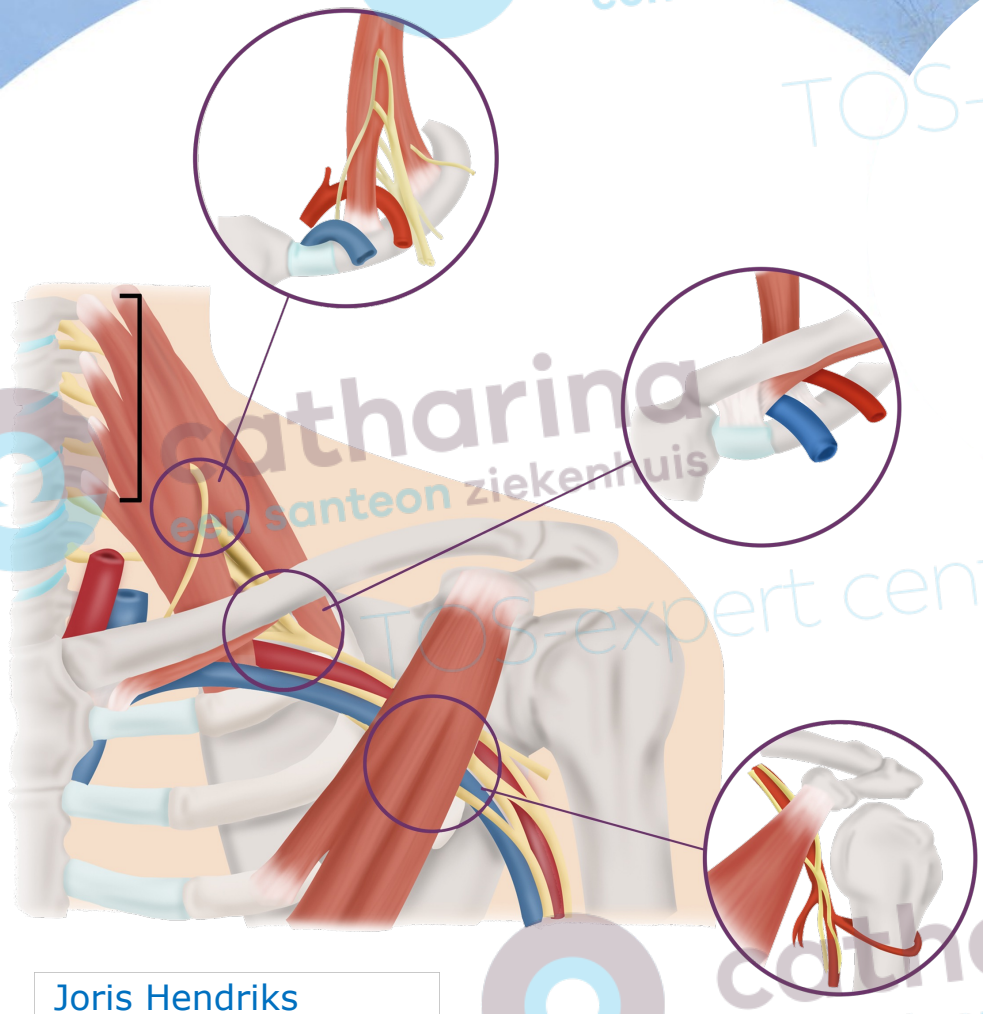

vTOS

Venous Thoracic Outlet Syndrome

Diagnostiek & behandeling

Joris Hendriks
Interventieradioloog

Disclosures

- Sponsering Medtronic van dit event

Richtlijn diagnostiek bij vTOS

ACR Appropriateness Criteria Imaging in the Diagnosis of Thoracic Outlet Syndrome

J Am Coll Radiol 2015;12:438-443.

Variant 1. Imaging in the diagnosis of thoracic outlet syndrome

Radiologic Procedure	Rating	Comments	Relative Radiation Level
X-ray chest	8		☢
MRA chest without and with contrast	8	See statement regarding contrast in text under "Anticipated Exceptions."	O
CTA chest with contrast	7		☢☢☢
MRI chest without contrast	7		O
Ultrasound duplex Doppler subclavian artery and vein	6		O
Digital subtraction angiography upper extremity	5		☢
CT chest without contrast	3		☢☢☢
MRA chest without contrast	2		O

Note: Rating scale: 1, 2, and 3 = usually not appropriate; 4, 5, and 6 = may be appropriate; 7, 8, and 9 = usually appropriate. CTA = CT angiography; MRA = MR angiography.

ACR Appropriateness Criteria®
Thoracic Outlet Syndrome

J Am Coll Radiol 2020;17:S323-S334.

Variant 1. Neurogenic thoracic outlet syndrome. Initial imaging and follow-up imaging after surgery or intervention.

Procedure	Appropriateness Category	Relative Radiation Level
MRI chest without and with IV contrast	Usually Appropriate	O
MRI chest without IV contrast	Usually Appropriate	O
Radiography chest	Usually Appropriate	☢
CT chest with IV contrast	May	
CTA chest with IV contrast	May	
US duplex Doppler subclavian artery and vein	May	
CT chest without and with IV contrast	Usually	
CT chest without IV contrast	Usually	
CTV chest with IV contrast	Usually	
MRA chest without and with IV contrast	Usually	
MRA chest without IV contrast	Usually	
Catheter venography upper extremity	Usually	
MRV chest without and with IV contrast	Usually	
MRV chest without IV contrast	Usually	
Arteriography upper extremity	Usually	

Variant 2. Venous thoracic outlet syndrome. Initial imaging and follow-up imaging after surgery or intervention.

Procedure	Appropriateness Category	Relative Radiation Level
Catheter venography upper extremity	Usually Appropriate	☢☢☢
US duplex Doppler subclavian artery and vein	Usually Appropriate	O
CT chest with IV contrast	Usually	
Radiography chest	Usually	
CTV chest with IV contrast	May Be	
MRI chest without and with IV contrast	May Be	
MRV chest without and with IV contrast	May Be	
MRA chest without and with IV contrast	May Be	
MRA chest without IV contrast	May Be Appro	
MRI chest without IV contrast	May Be	
MRV chest without IV contrast	May Be	
CT chest without IV contrast	May Be	
CT chest without and with IV contrast	Usually N	
Arteriography upper extremity	Usually N	
CTA chest with IV contrast	Usually N	

Variant 3. Arterial thoracic outlet syndrome. Initial imaging and follow-up imaging after surgery or intervention.

Procedure	Appropriateness Category	Relative Radiation Level
CTA chest with IV contrast	Usually Appropriate	☢☢☢
MRA chest without and with IV contrast	Usually Appropriate	O
Radiography chest	Usually Appropriate	☢
US duplex Doppler subclavian artery and vein	Usually Appropriate	O
Arteriography upper extremity	Usually Appropriate	☢
CT chest with IV contrast	May Be Appropriate	☢☢☢
MRI chest without and with IV contrast	May Be Appropriate	O
MRA chest without IV contrast	May Be Appropriate	O
MRI chest without IV contrast	May Be Appropriate	O
CT chest without IV contrast	May Be Appropriate	☢☢☢
CT chest without and with IV contrast	Usually Not Appropriate	☢☢☢
Catheter venography upper extremity	Usually Not Appropriate	☢☢☢
CTV chest with IV contrast	Usually Not Appropriate	☢☢☢☢
MRV chest without and with IV contrast	Usually Not Appropriate	O
MRV chest without IV contrast	Usually Not Appropriate	O

ACR Appropriateness Criteria®
Thoracic Outlet Syndrome

J Am Coll Radiol 2020;17:S323-S334.

Variant 2. Venous thoracic outlet syndrome. Initial imaging and follow-up imaging after surgery or intervention.

Procedure	Appropriateness Category	Relative Radiation Level
Catheter venography upper extremity	Usually Appropriate	☢☢☢
US duplex Doppler subclavian artery and vein	Usually Appropriate	O
CT chest with IV contrast	Usually Appropriate	☢☢☢
Radiography chest	Usually Appropriate	☢
CTV chest with IV contrast	May Be Appropriate	☢☢☢☢
MRI chest without and with IV contrast	May Be Appropriate	O
MRV chest without and with IV contrast	May Be Appropriate	O
MRA chest without and with IV contrast	May Be Appropriate	O
MRA chest without IV contrast	May Be Appropriate (Disagreement)	O
MRI chest without IV contrast	May Be Appropriate	O
MRV chest without IV contrast	May Be Appropriate	O
CT chest without IV contrast	May Be Appropriate	☢☢☢
CT chest without and with IV contrast	Usually Not Appropriate	☢☢☢
Arteriography upper extremity	Usually Not Appropriate	☢
CTA chest with IV contrast	Usually Not Appropriate	☢☢☢

SUMMARY OF RECOMMENDATIONS

- **Variant 1:** Radiography of the chest and either MRI without and with IV contrast of the chest or MRI without IV contrast of the chest are usually appropriate for the initial and follow-up imaging after surgery or intervention for patients with nTOS. MRI without IV contrast is an acceptable alternative to MRI without and with IV contrast (ie, only one procedure will be ordered to provide the clinical information to effectively manage the patient's care).
- **Variant 2:** Radiography of the chest and US duplex

vention for patients with vTOS. US duplex Doppler, CT with IV contrast, and catheter venography are equivalent alternatives (ie, only one procedure will be ordered to provide the clinical information to effectively manage the patient's care). The panel did not

the chest for the initial and follow-up imaging after surgery or intervention for patients with venous thoracic outlet syndrome. There is insufficient medical literature to conclude whether or not these patients would benefit from MRA without IV contrast of the chest for this clinical scenario. Imaging in this patient population is controversial but may be appropriate.

- **Variant 3:** Radiography of the chest and CTA with IV contrast of the chest, MRA without and with IV contrast of the chest, US duplex Doppler of the subclavian artery and vein, or arteriography of the upper extremity are usually appropriate for the initial and follow-up imaging after surgery or intervention for patients with aTOS. CTA with IV contrast, MRA without and with IV contrast, US duplex Doppler, and arteriography of the upper extremity are equivalent alternatives (ie, only one procedure will be ordered to provide the clinical information to effectively manage the patient's care).

Huidige diagnostiek vTOS CZE

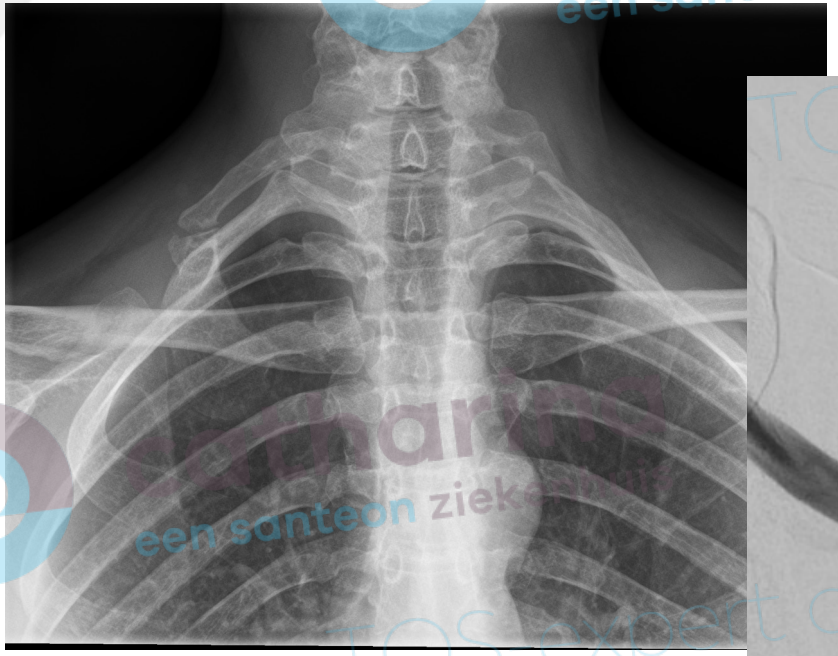

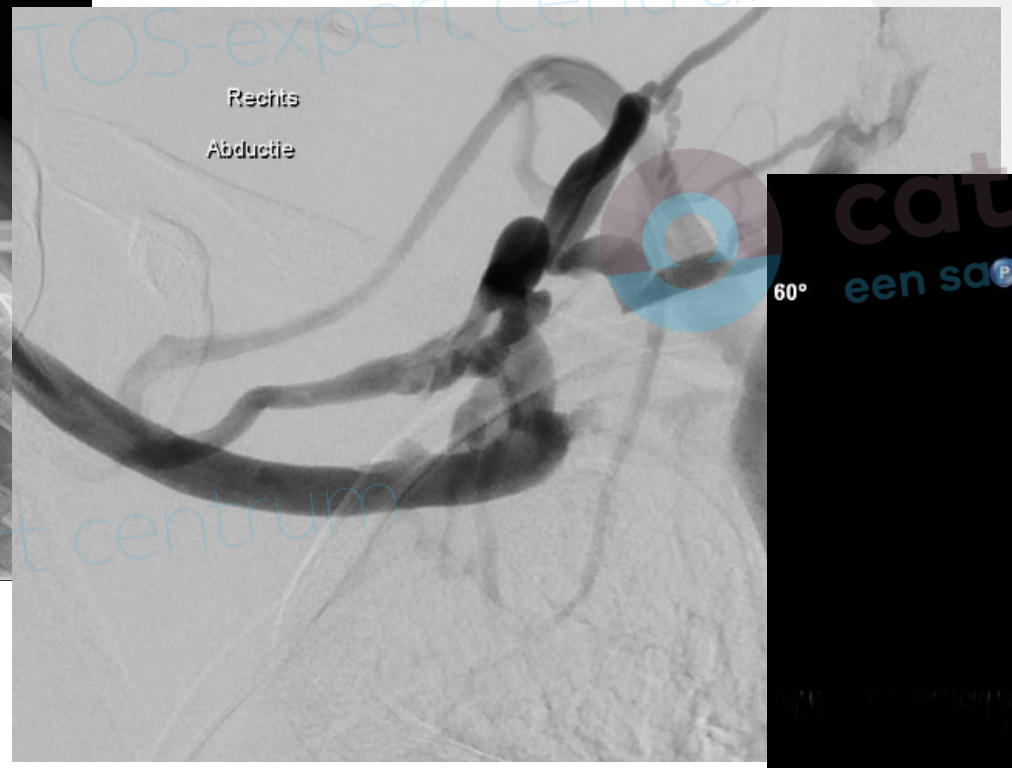

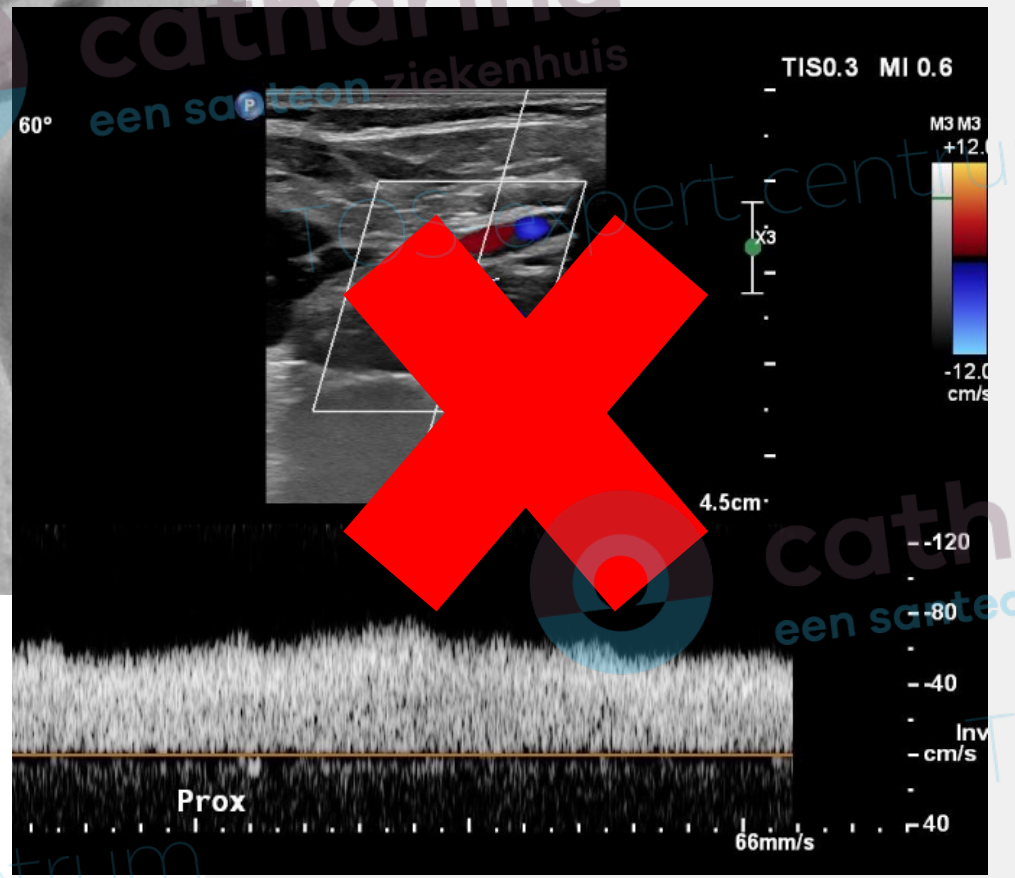

Duplex bij vTOS

False-negative upper extremity ultrasound in the initial evaluation of patients with suspected subclavian vein thrombosis due to thoracic outlet syndrome (Paget-Schroetter syndrome)

Evan R. Brownie, MD, Ahmmad A. Abuirqeba, BA, J. Westley Ohman, MD, Brian G. Rubin, MD, *and* Robert W. Thompson, MD, *St. Louis, Mo*

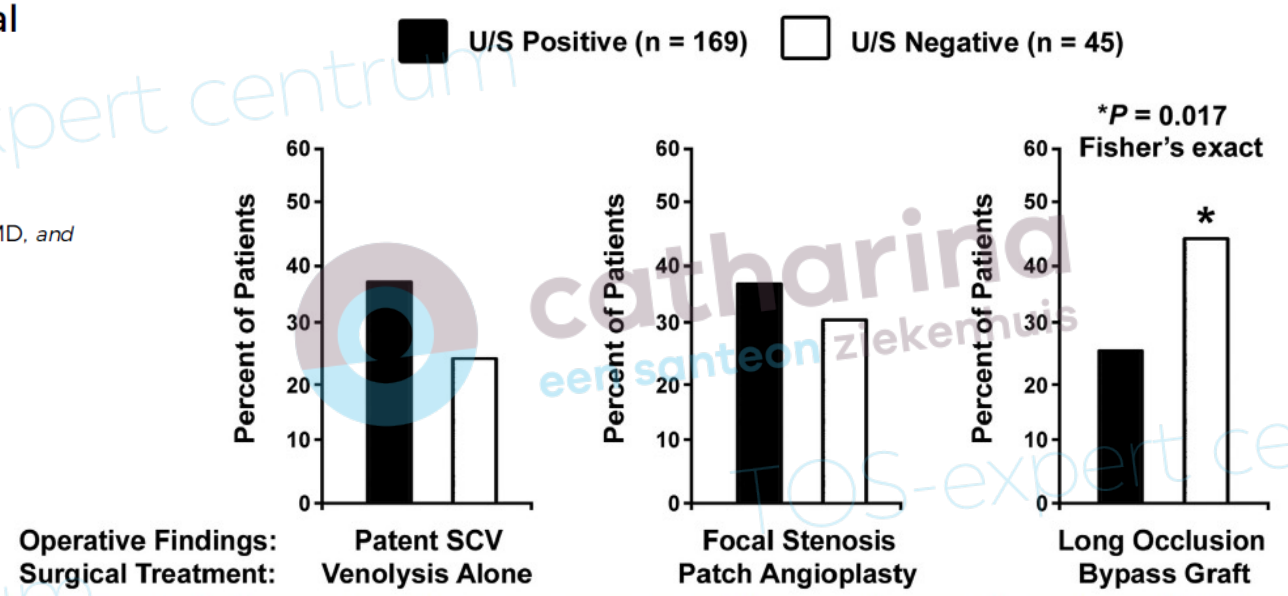

Fig 2. Operative findings and surgical treatment in patients with venous thoracic outlet syndrome (*VTOS*). Bar graphs illustrating the incidence of different operative findings and the surgical treatment performed for patients with VTOS, depending on the use of upper extremity ultrasound as the initial diagnostic test (positive ultrasound, black bars, n = 169; false-negative ultrasound, white bars, n = 45). *$P = .017$, Fisher's exact test. *SCV*, Subclavian vein; *U/S*, ultrasound.

Conclusions: Duplex ultrasound has significant limitations in the initial evaluation of patients with suspected SCV thrombosis, with false-negative results in 21% of patients with proven VTOS. This is rarely acknowledged in ultrasound reports, but false-negative ultrasound studies have the potential to delay definitive imaging, thrombolysis, and further treatment for VTOS. Initial false-negative ultrasound results are associated with progressive thrombus extension and a

Brownie ER et al. False-negative upper extremity ultrasound in the initial evaluation of patients with suspected subclavian vein thrombosis due to thoracic outlet syndrome (Paget-Schroetter syndrome). Journal of Vascular Surgery: Venous and Lymphatic Disorders. 2020: Volume 8; Number 1;118-126

Flebografie bij vTOS

- Voordelen:
  - Verschillende posities
  - “Flow dynamics”
  - Behandeling
  - Goed vergelijkingsmateriaal pre-, per- en postoperatief
  - Snel en makkelijk beschikbaar

- Nadelen:
  - Röntgenstraling
  - 2D beeld
  - Stenosegraad?
  - Invasief?

Same Admission Hybrid Treatment of Primary Upper Extremity Deep Venous Thrombosis with Thrombolysis, Transaxillary Thoracic Outlet Decompression, and Immediate Endovascular Evaluation

Niels Pesser,[1] Aron Bode,[1] Jens Goeteyn,[1] Joris Hendriks,[2] Bart F.L. van Nuenen,[3] Marc R.H.M. van Sambeek,[1,4] and Joep A.W. Teijink,[1,5] Eindhoven, The Netherlands

Annals of Vascular Surgery, 2021-02-01, Volume 71, Pages 249-256

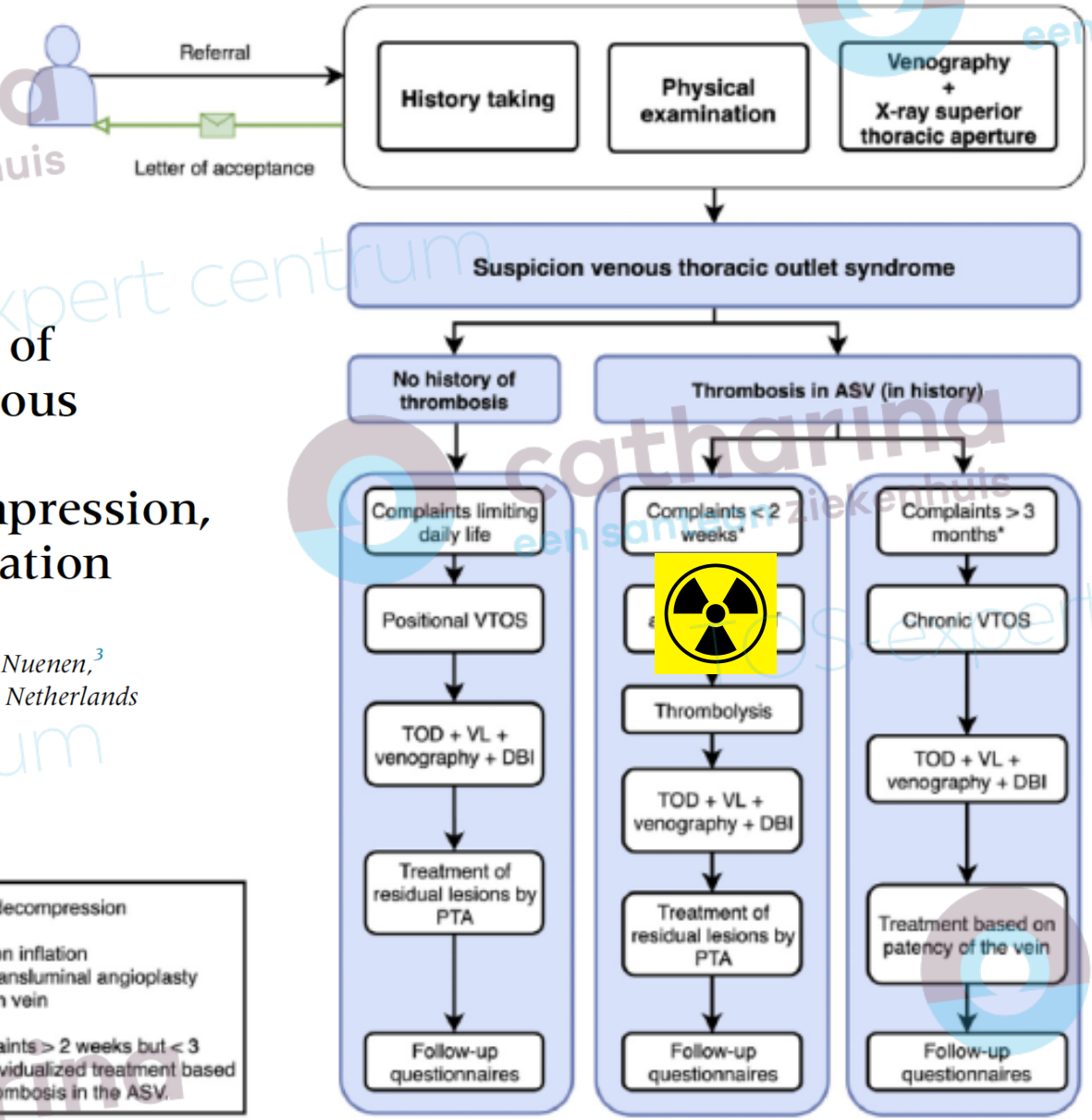

TOD: thoracic outlet decompression
VL: venolysis
DBI: diagnostic balloon inflation
PTA: percutaneous transluminal angioplasty
ASV: axillo-subclavian vein

* Patients with complaints > 2 weeks but < 3 months recieve an individualized treatment based on the presence of thrombosis in the ASV.

Fig. 1. Care pathway for VTOS including the pUEDVT treatment algorithm.

Diagnostiek bij acute vTOS

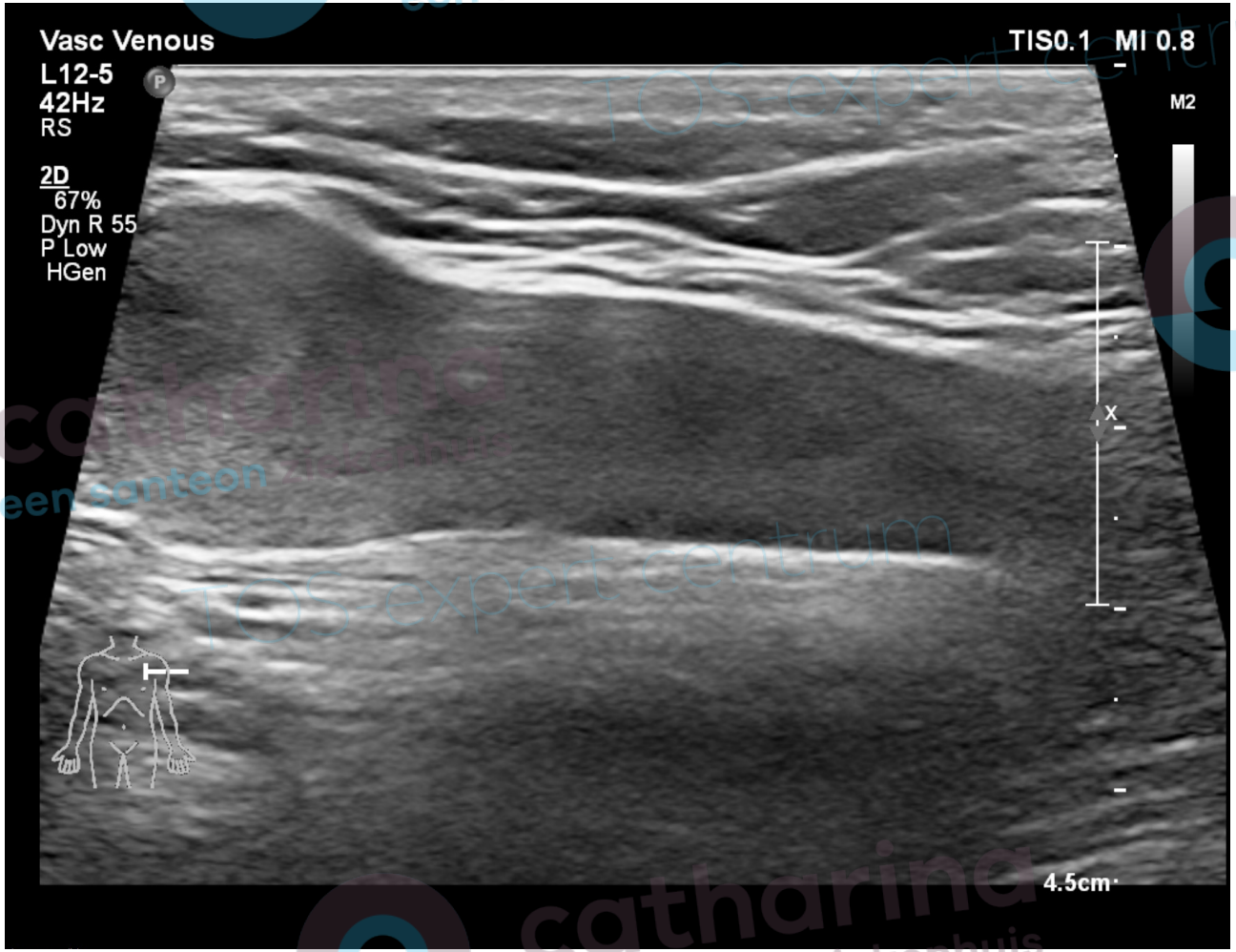

- Man 23 jaar
- Blanco VG
- via de huisarts naar SEH
  - Wakker geworden met dikke rode linker arm
  - Sensibiliteit en motoriek intact
  - Geen immobilisatie
  - Niet ziek geweest

Behandeling bij acute vTOS

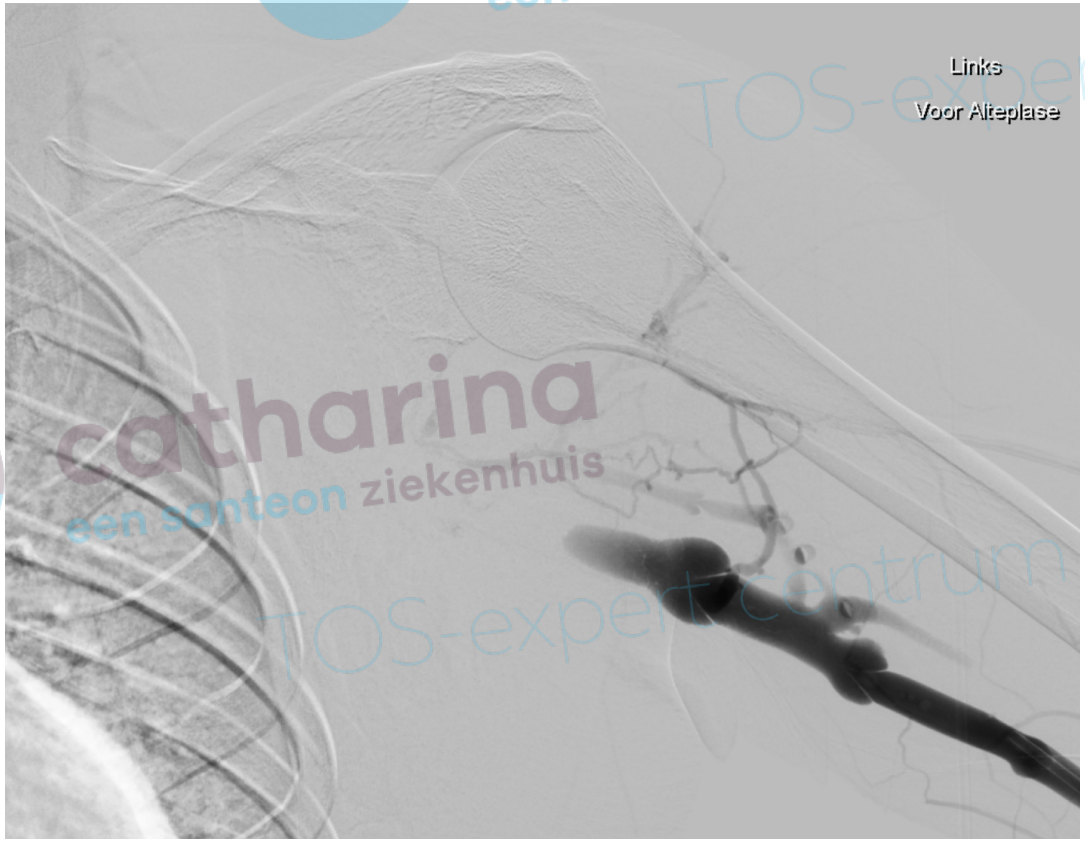

Flebografie na sheathplaatsing

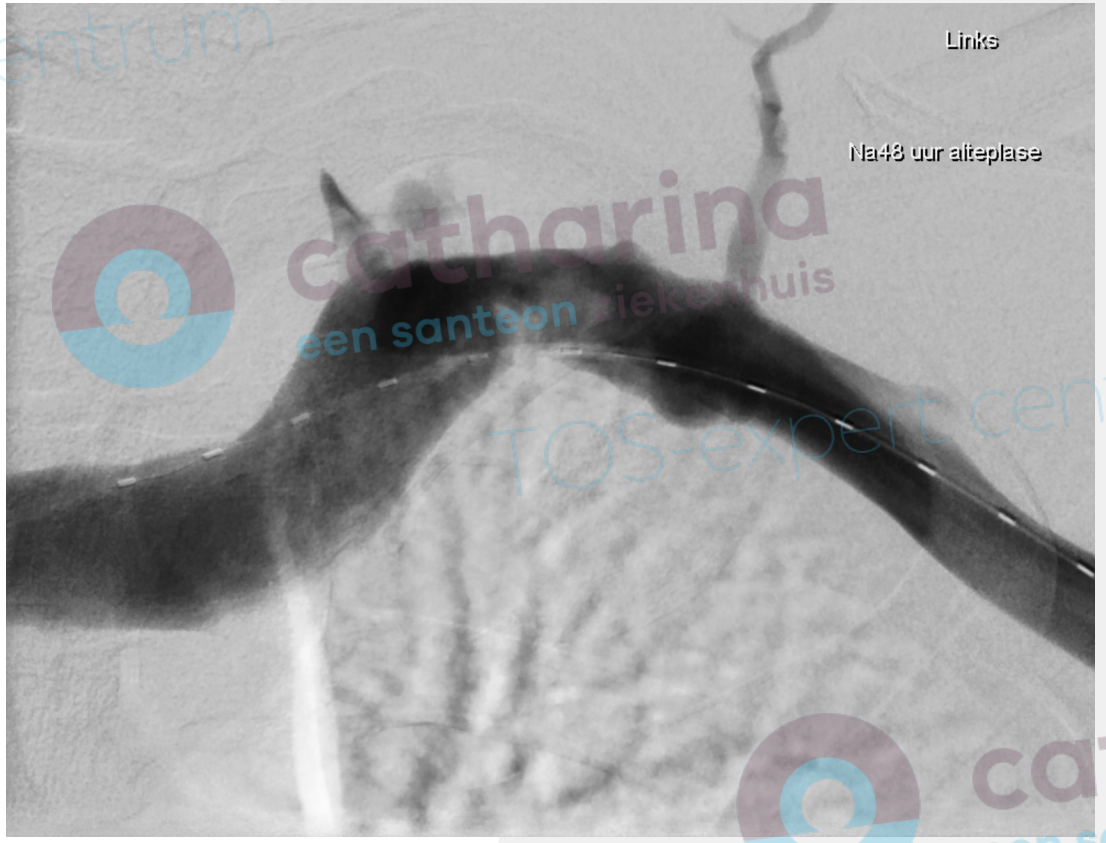

Na 48 uur trombolyse

Behandeling bij acute vTOS

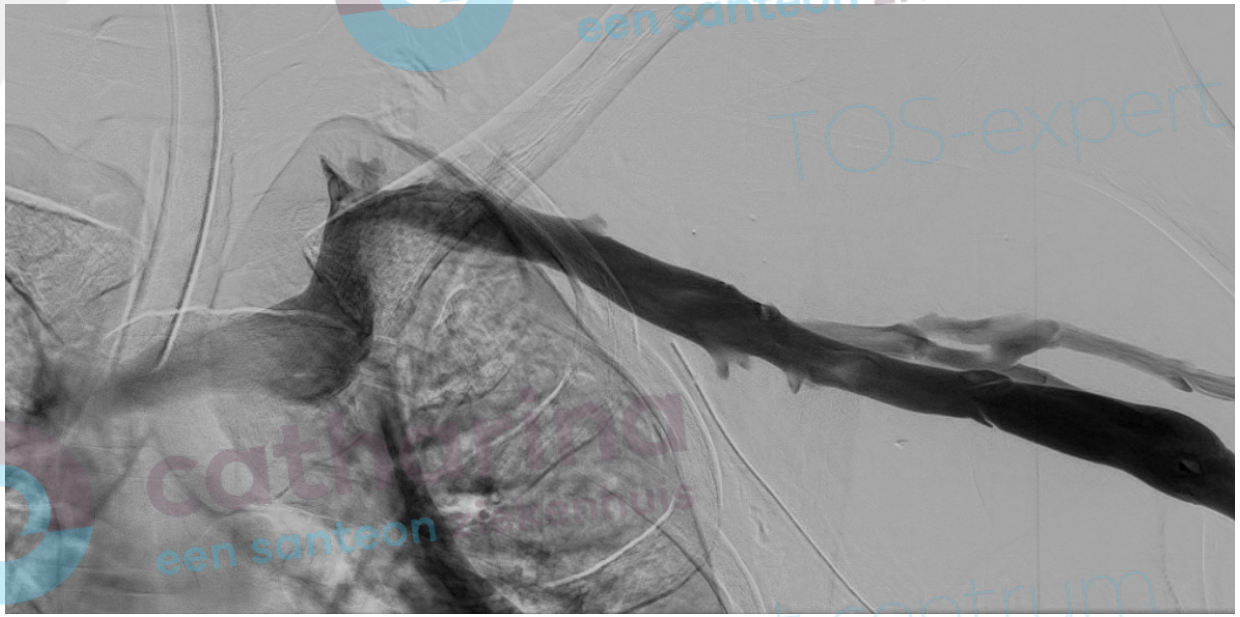

Flebografie postTOD

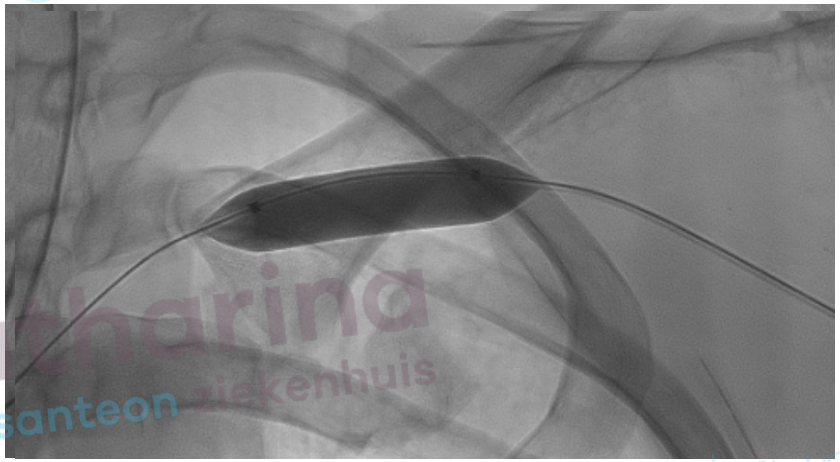

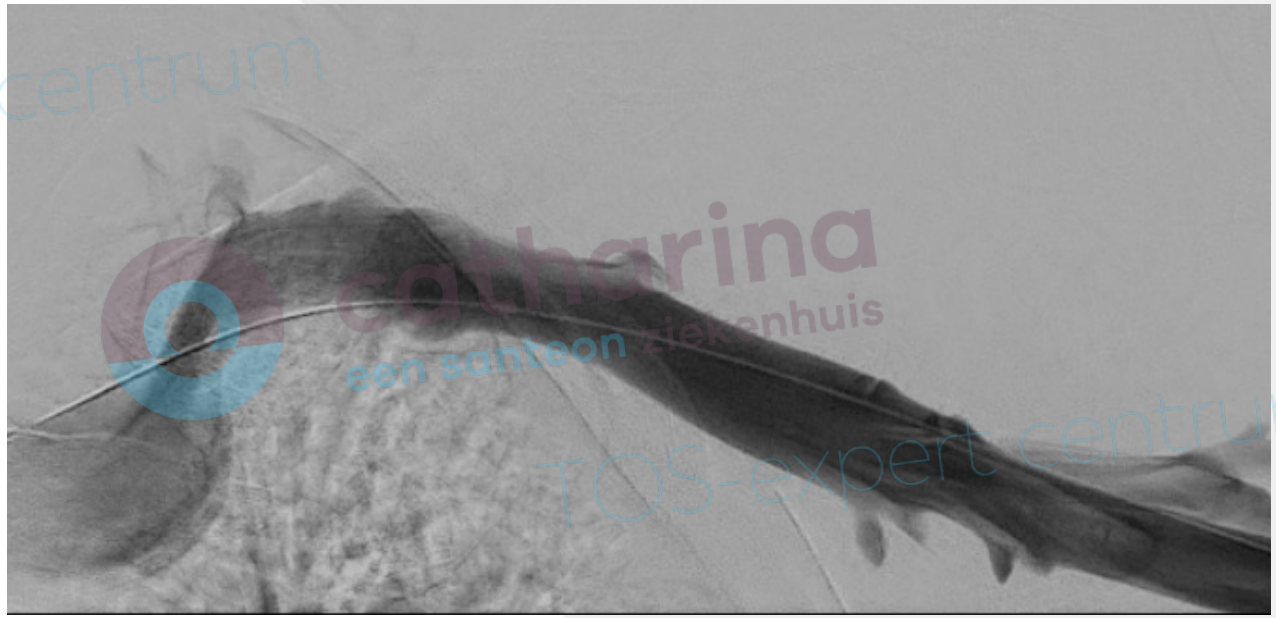

Flebografie postTOD & postPTA

Same Admission Hybrid Treatment of Primary Upper Extremity Deep Venous Thrombosis with Thrombolysis, Transaxillary Thoracic Outlet Decompression, and Immediate Endovascular Evaluation

Niels Pesser,[1] Aron Bode,[1] Jens Goeteyn,[1] Joris Hendriks,[2] Bart F.L. van Nuenen,[3] Marc R.H.M. van Sambeek,[1,4] and Joep A.W. Teijink,[1,5] Eindhoven, The Netherlands

Annals of Vascular Surgery, 2021-02-01, Volume 71, Pages 249-256

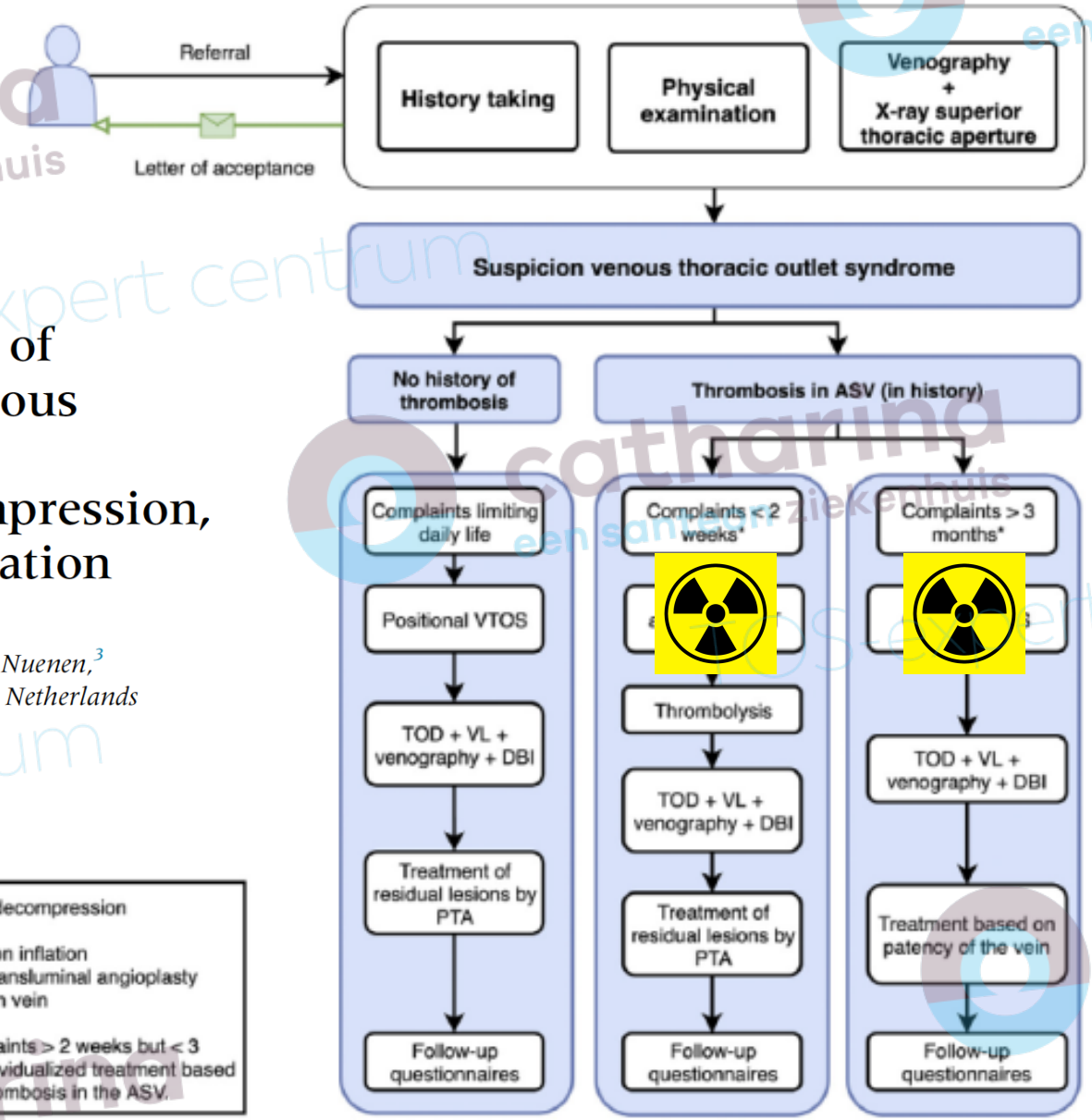

TOD: thoracic outlet decompression
VL: venolysis
DBI: diagnostic balloon inflation
PTA: percutaneous transluminal angioplasty
ASV: axillo-subclavian vein

* Patients with complaints > 2 weeks but < 3 months recieve an individualized treatment based on the presence of thrombosis in the ASV.

Fig. 1. Care pathway for VTOS including the pUEDVT treatment algorithm.

Diagnostiek volgens chronische vTOS-protocol

- Poliklinische afspraak angiokamer
- Echo v. subclavia
- Echogeleid infuus in de v. basilica of v. brachialis
- 4 houdingen flebografie (20ml met 50% contrast en 50% NaCl)
  - Neutraal (arm omlaag)
  - Military attitude (borst vooruit)
  - Abductie (arm omhoog)
  - Adductie (hand op contralaterale schouder)

Diagnostiek volgens chronische vTOS-protocol

Infuus in de elleboogsplooi

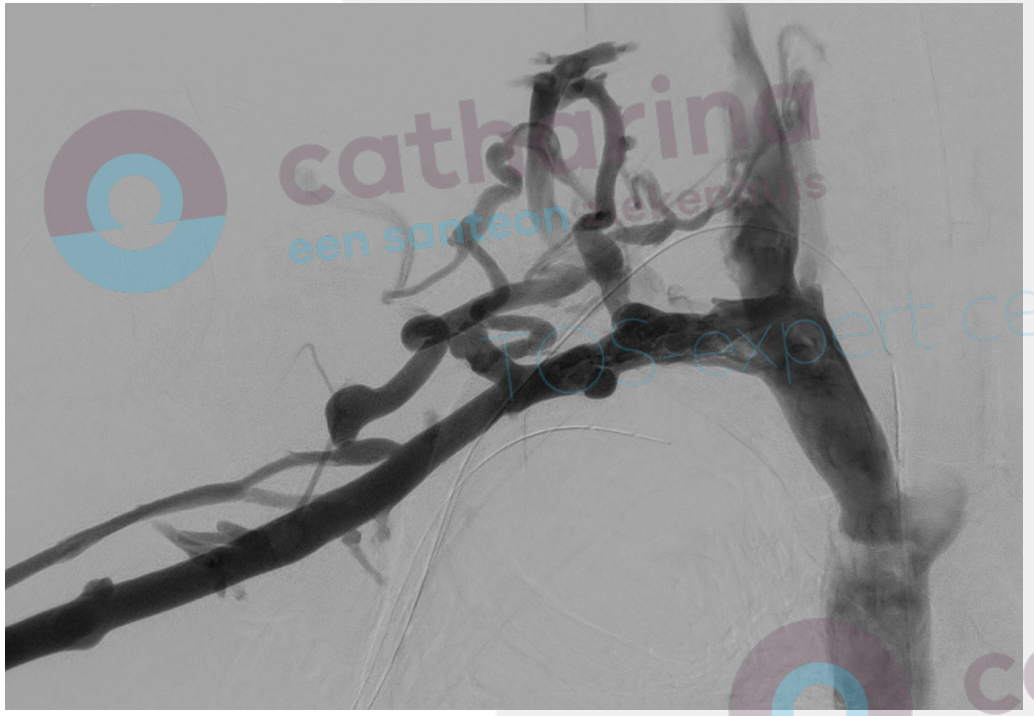

Flebografie postTOD via de v. basilica

Veel voorkomende casus chronische vTOS

- Vrouw 26 jaar
- Via huisarts verdenking n/vTOS
- Syptomen van trombose arm (paarsverkleuring, zwelling en pijn) op 16 jarige leeftijd. Werd gemeld zo mee te leven.
- Al jaren last van tintelingen en doof gevoel arm en vingers. Ook stuwingsklachten en witverkleuring arm
- Lichamelijk onderzoek suspect n/vTOS

TOS expert center

4 houdingen flebografie

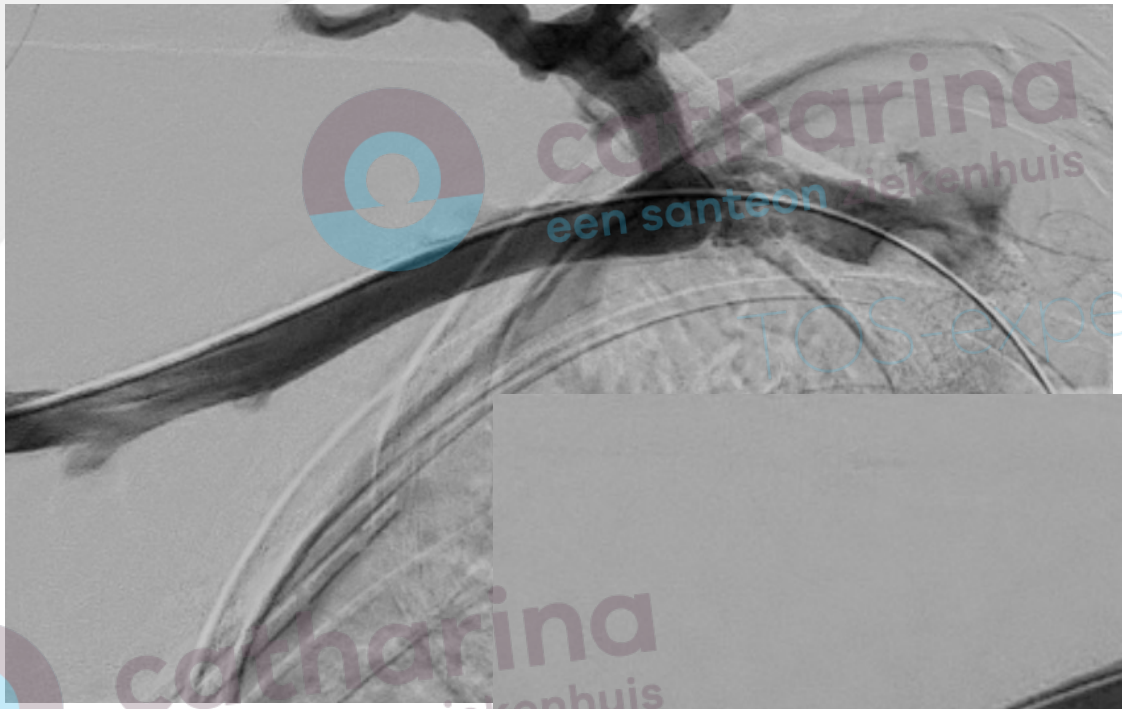

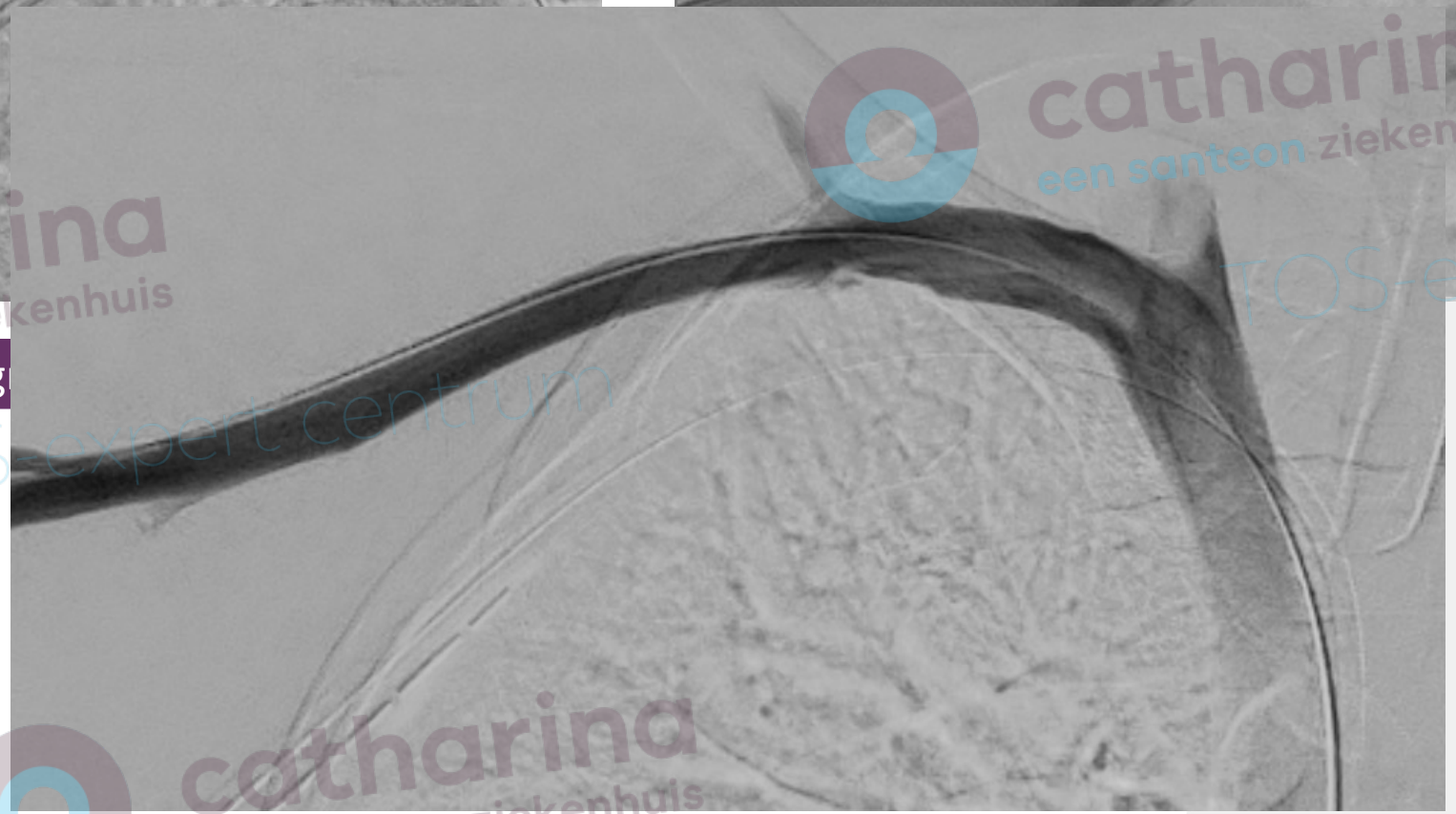

Flebog

Flebografie postTOD en postPTA

Casus chronische vTOS

- Vrouw 19 jaar
- Okt 2021 trombose arm rechts wv DOAC
- Okt 2021 analyse hematologie: Factor V Leiden en orale anticonceptie
- Nov 2021 Verwijzing vanuit vaatchirurgie ivm verdenking chronische vTOS met PTS

Casus chronische vTOS

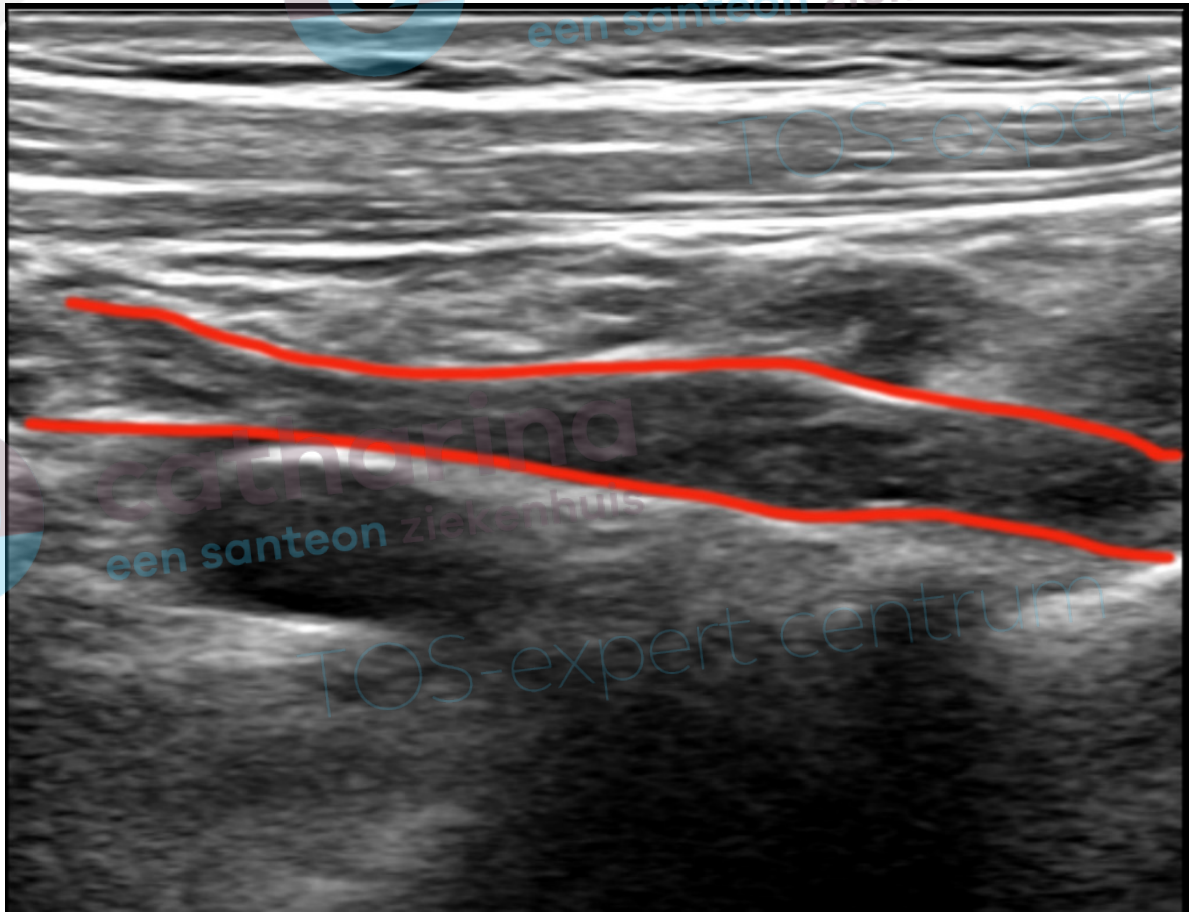

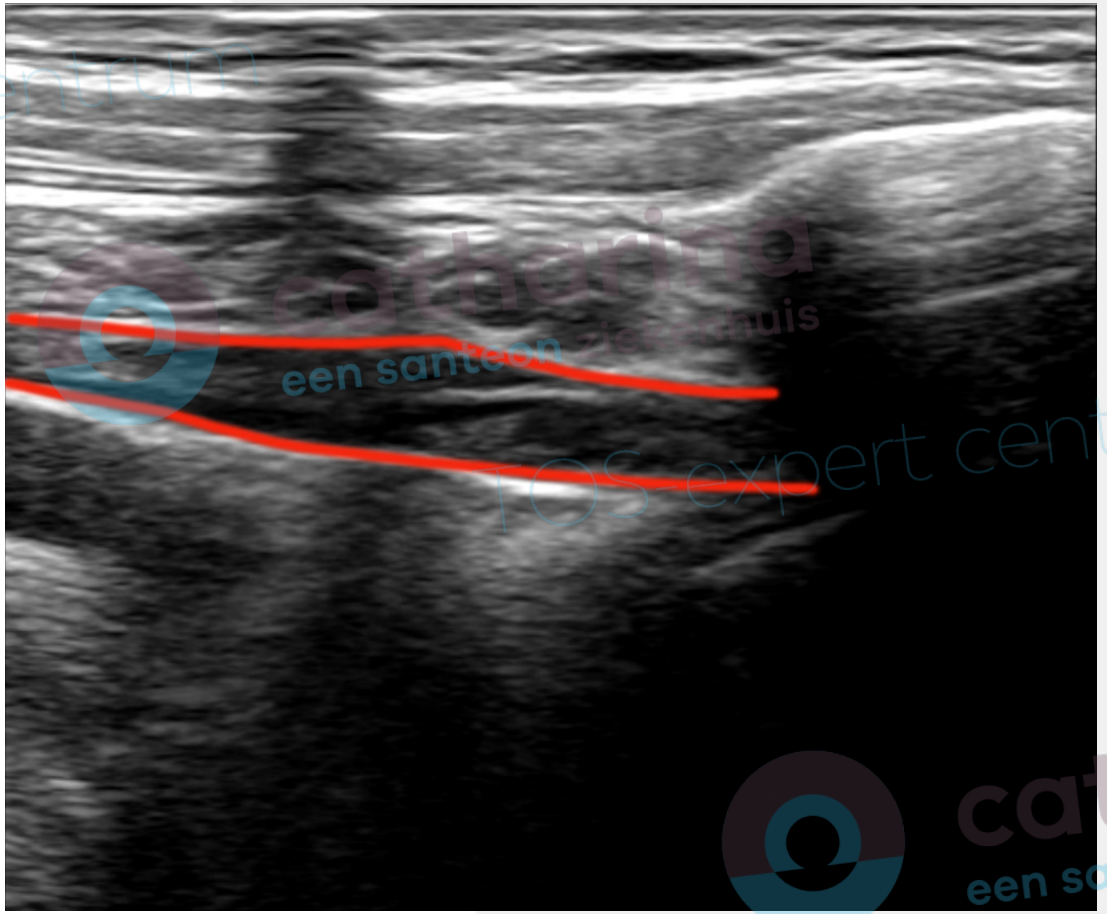

Echografie voorafgaand aan de 4 houdingen flebografie

TOS expert center

Casus chronische vTOS

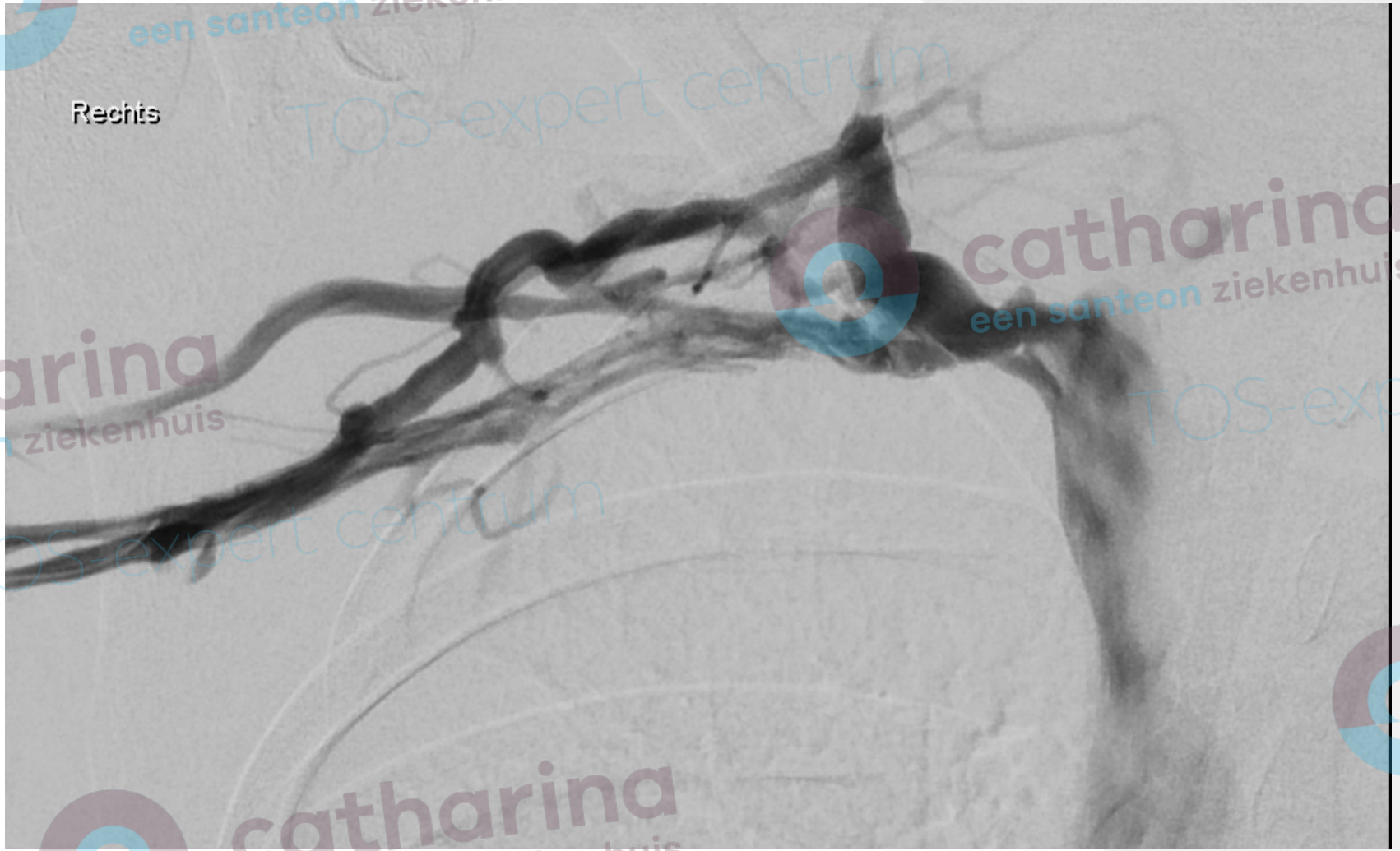

Flebografie na sheathplaatsing voor een proefrekanalisatie

Casus chronische vTOS

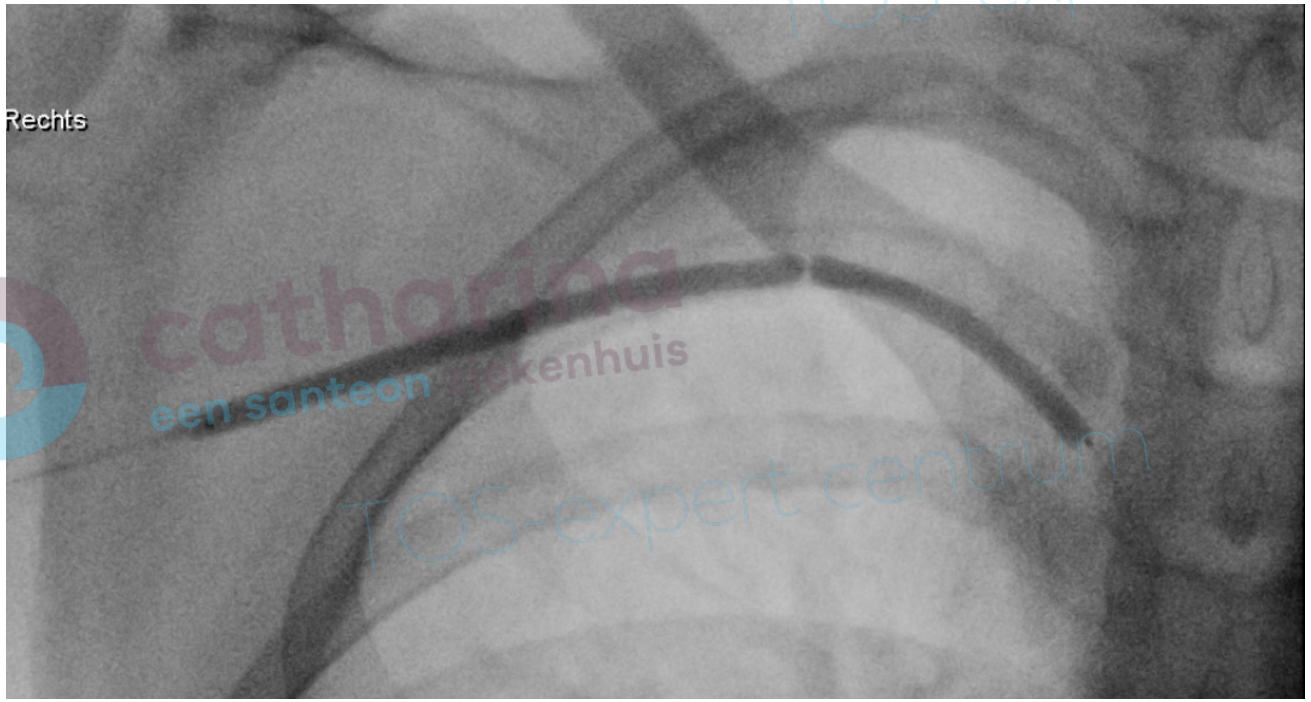

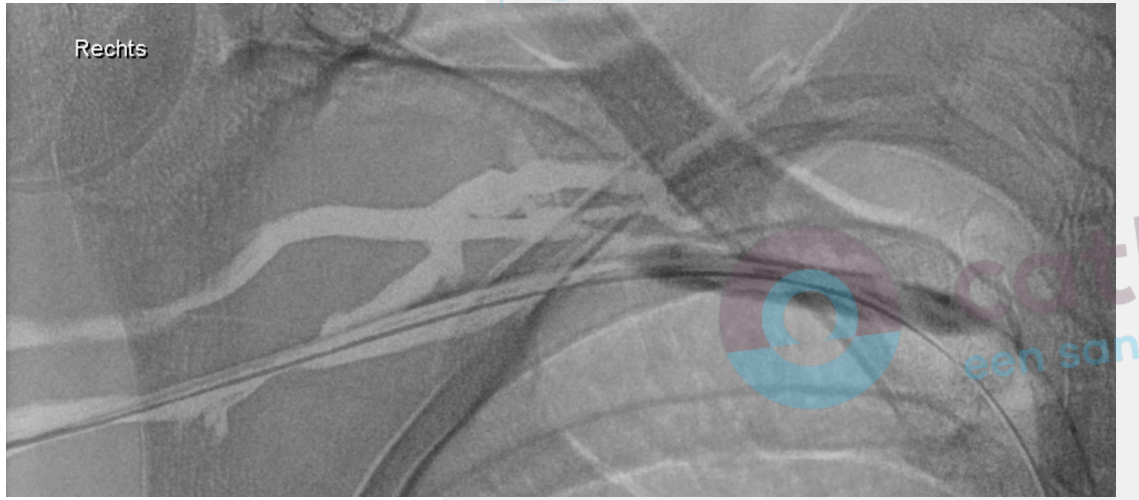

Casus chronische vTOS

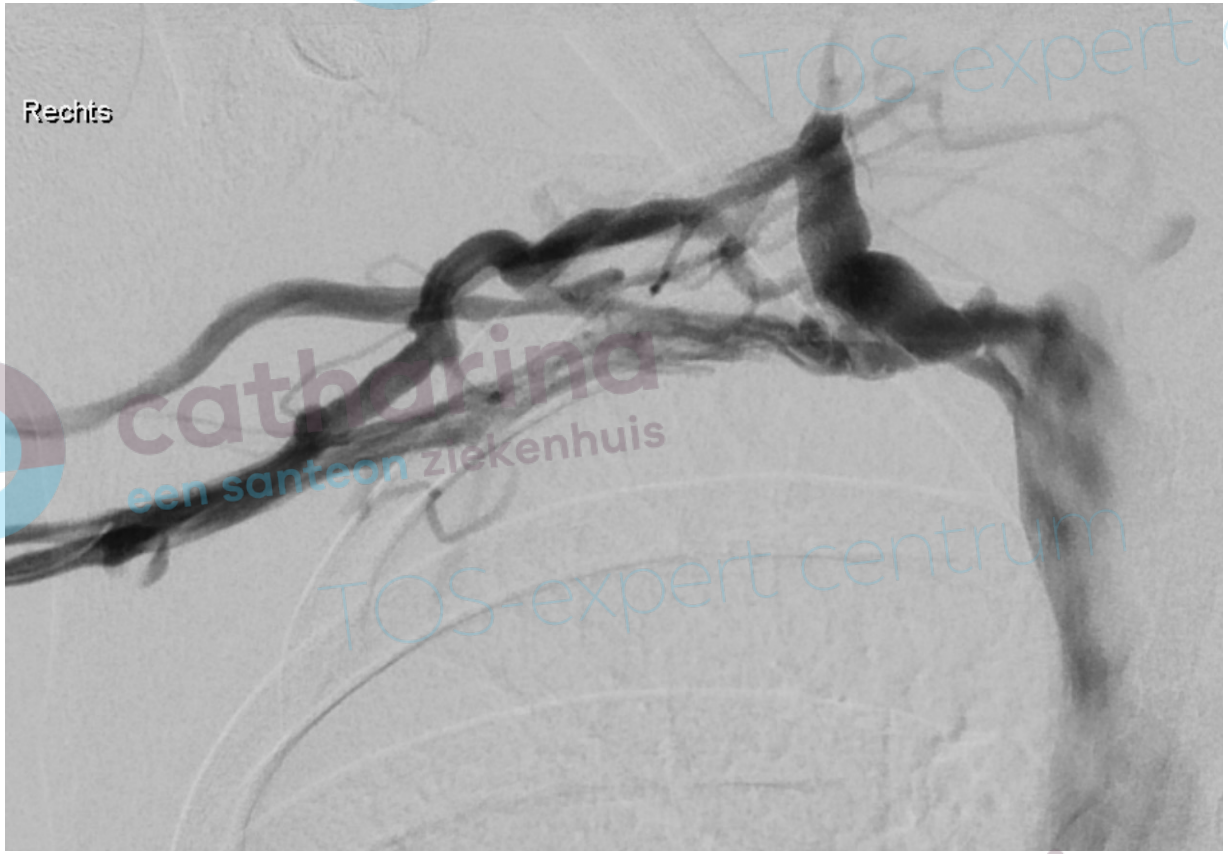

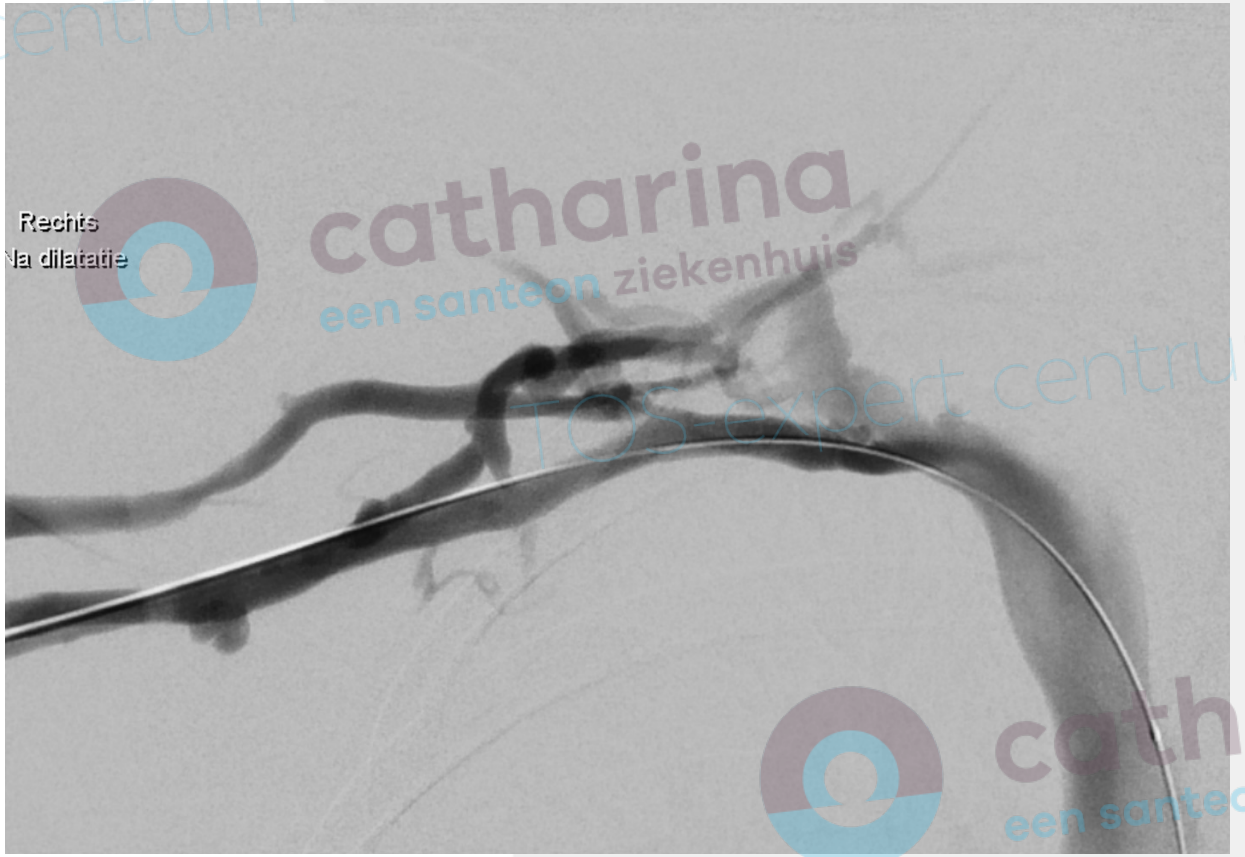

Flebografie voor en na PTA

Casus chronische vTOS

Flebografie voor en na PTA

Significante stenose flebografie?

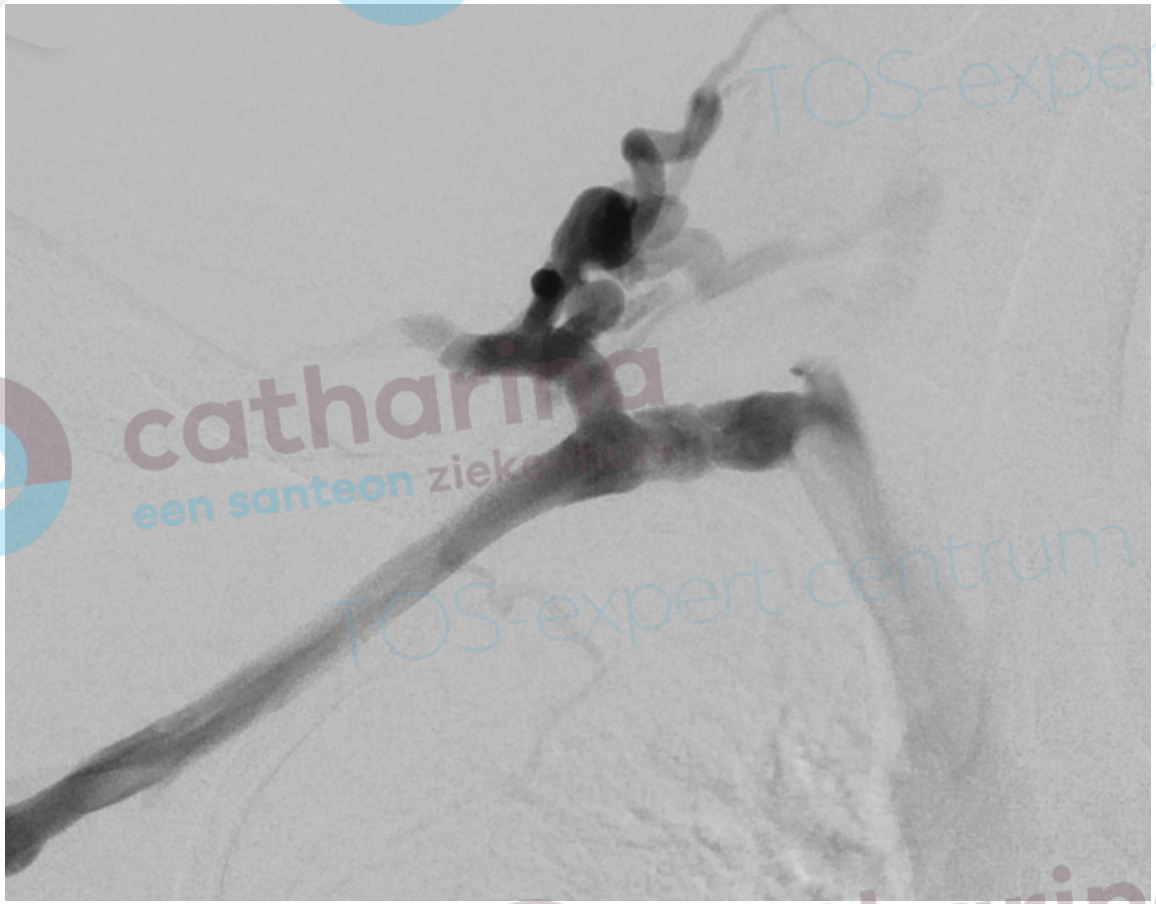

1e casus

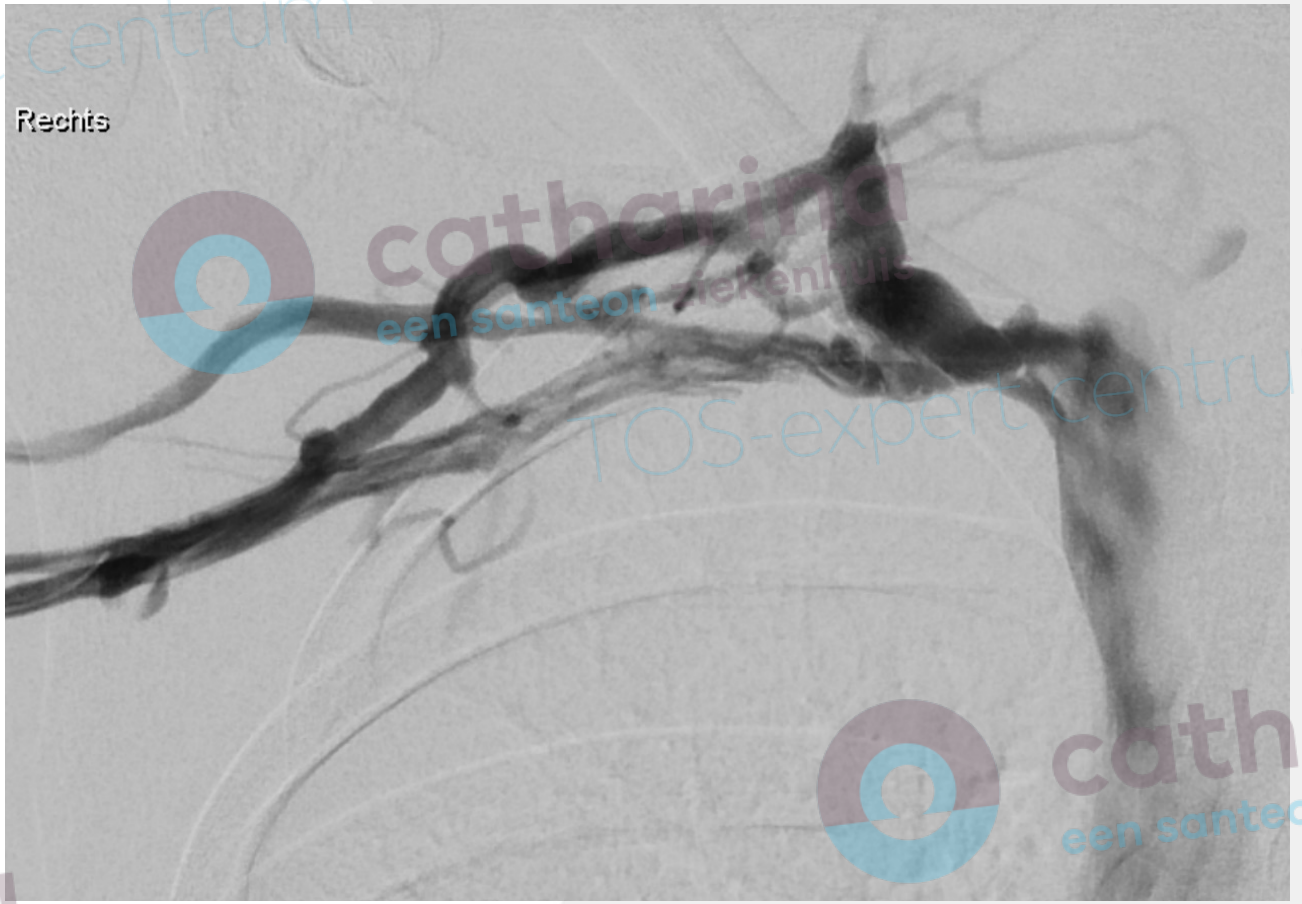

2e casus

Significante stenose flebografie?

- Anders dan arterieel waar algemeen geaccepteerde afkapwaarde zijn

- 50% lumenreductie wordt genoemd[1,2],maar wetenschappelijke onderbouwing is er niet

- Wij zijn van mening dat een significante stenose moet worden gesteld op een combinatie van lumenreductie, aanwezigheid van collateralen en bloedstroombelemmering door intraluminale synechiae/webs.

1. Villalba L, Larkin TA. Transabdominal duplex ultrasound and intravascular ultrasound planimetry measures of common iliac vein stenosis are significantly correlated in a symptomatic population. *J Vasc Surg Venous Lymphat Disord*. 2021;9(5):1273-1281. doi:10.1016/j.jvsv.2021.01.015
2. Labropoulos N, Borge M, Pierce K, Pappas PJ. Criteria for defining significant central vein stenosis with duplex ultrasound. *J Vasc Surg*. 2007;46(1):101-107. doi:10.1016/j.jvs.2007.02.062

TOS expert center

IVUS bij vTOS

Intravascular ultrasonography provides more sensitive detection of subclavian vein stenosis than venography in patients presenting with Paget-Schroetter syndrome

Jesus G. Ulloa, MD, Hugh A. Gelabert, MD, Jessica B. O'Connell, MD, Rhusheet Patel, MD, *and* David A. Rigberg, MD, *Los Angeles, Calif*

https://doi.org/10.1016/j.jvsv.2020.12.068

ARTICLE HIGHLIGHTS

- **Type of Research:** A single-center retrospective cohort study
- **Key Findings:** Intravascular ultrasonography (IVUS) is more sensitive in detecting subclavian vein stenosis than venography. In 10 of 35 patients (28%) in whom venography identified no significant stenosis, IVUS identified significant stenosis (33.5% craniocaudal, 54.3% anteroposterior, and 68.7% cross-sectional area; $P < .05$).
- **Take Home Message:** IVUS identified significant stenosis in patients in whom venography failed to do so. The greatest utility of IVUS is in the evaluation of patients with Paget-Schroetter syndrome in whom venography showed no evident compression.

Intravascular Ultrasound in Venous Thoracic Outlet Syndrome

Tanner I. Kim, Timur P. Sarac, and Kristine C. Orion, New Haven, Connecticut

Ann Vasc Surg 2019; 54: 118–122
https://doi.org/10.1016/j.avsg.2018.08.077

Manuscript received: January 31, 2018; manuscript accepted: August 6, 2018; published online: 11 September 2018

CONCLUSION

These results suggest that IVUS detected greater levels of stenosis than venography, leading to more interventions. Just as IVUS has become ideal for identifying occult iliac venous lesions, it may have a similar role in identifying venous lesions not evident on single-plane venography for postsurgical decompression vTOS patients.

TOS expert center

IVUS bij vTOS

Utilizing Provocative Maneuvers Intraoperatively in Conjunction With IVUS to Diagnose vTOS

The New Gold Standard

Hafez Golzarian, DO,[a] Jannet Bux, DO,[a] Alaha Mariam, MD,[a] Sidra R. Shah, DO,[a] Benjamin A. Pasley, DO,[a] Kyle R. Henneke, MD,[a] Manu B. Aggarwal, MD,[b] Sandeep M. Patel, MD[c]

JACC: CASE REPORTS, VOL. 4, NO. 15, 2022
AUGUST 3, 2022:950–954

CONCLUSIONS

We believe the use of the Wright test or its modified variations during intervention with simultaneous IVUS significantly increases the accuracy in determining the etiology of PSS or vTOS, especially when it is secondary to a mechanical anatomic obstruction. As of now, the approaches to diagnosing and managing TOS continue to remain variable and controversial. However, we believe this approach has the potential to serve as the new gold standard. Additional studies will be needed to help validate this claim.

IVUS versus PMI

- Wat is IVUS?
  - Intravascular Ultra Sound
  - Katheter met echokop om stenose van “binnenuit” te zien en te meten

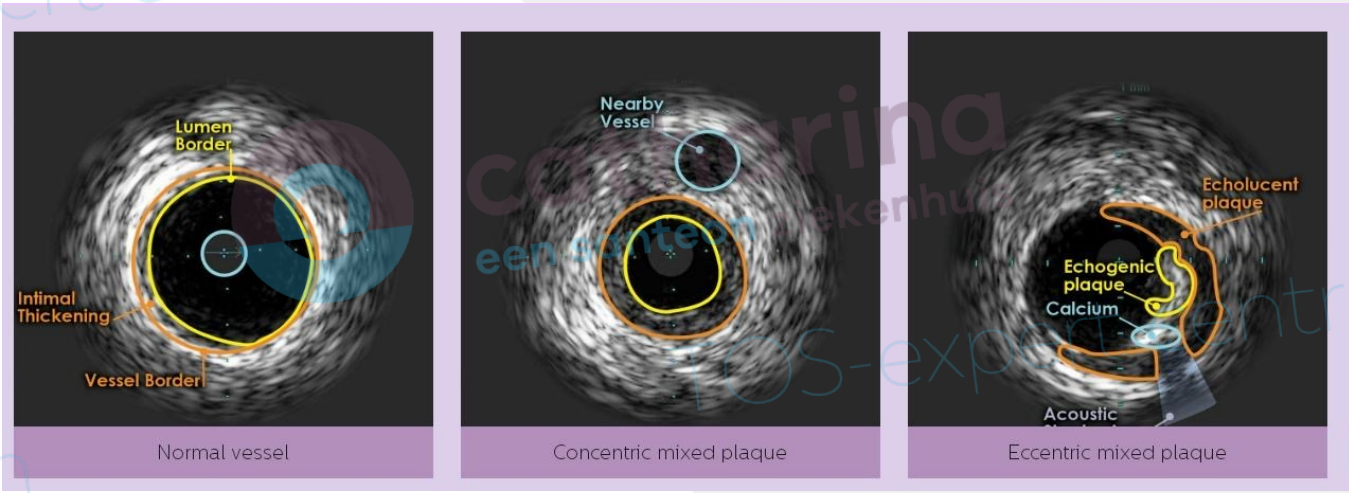

- Wat is PMI?
  - Poor Man’s IVUS
  - Indentatie van ballon of stent door stenose

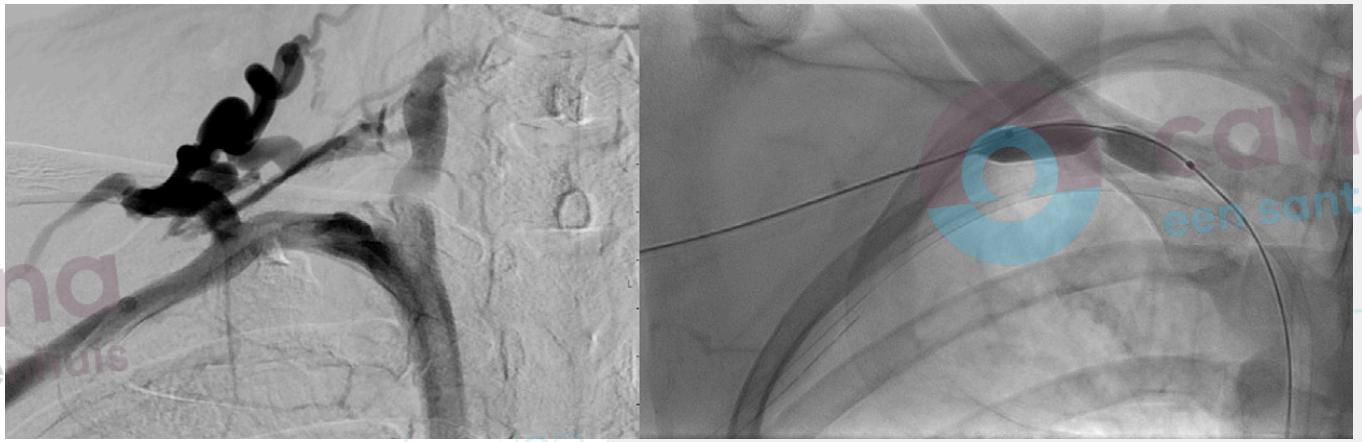

IVUS versus PMI

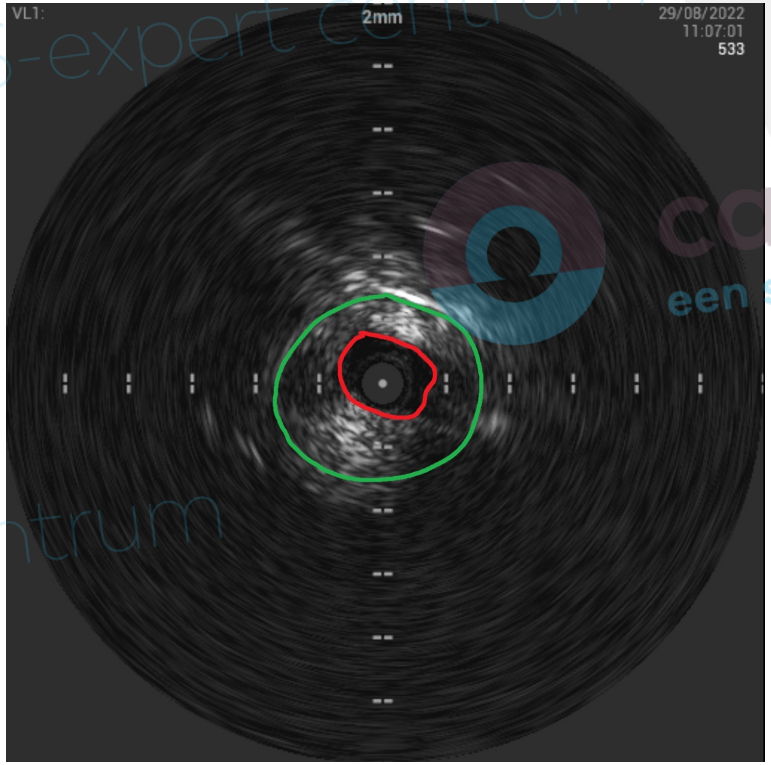

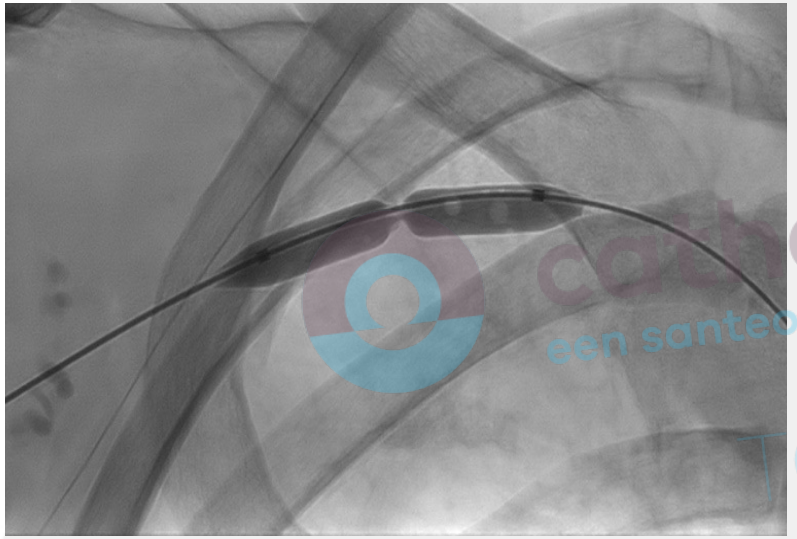

IVUS versus PMI

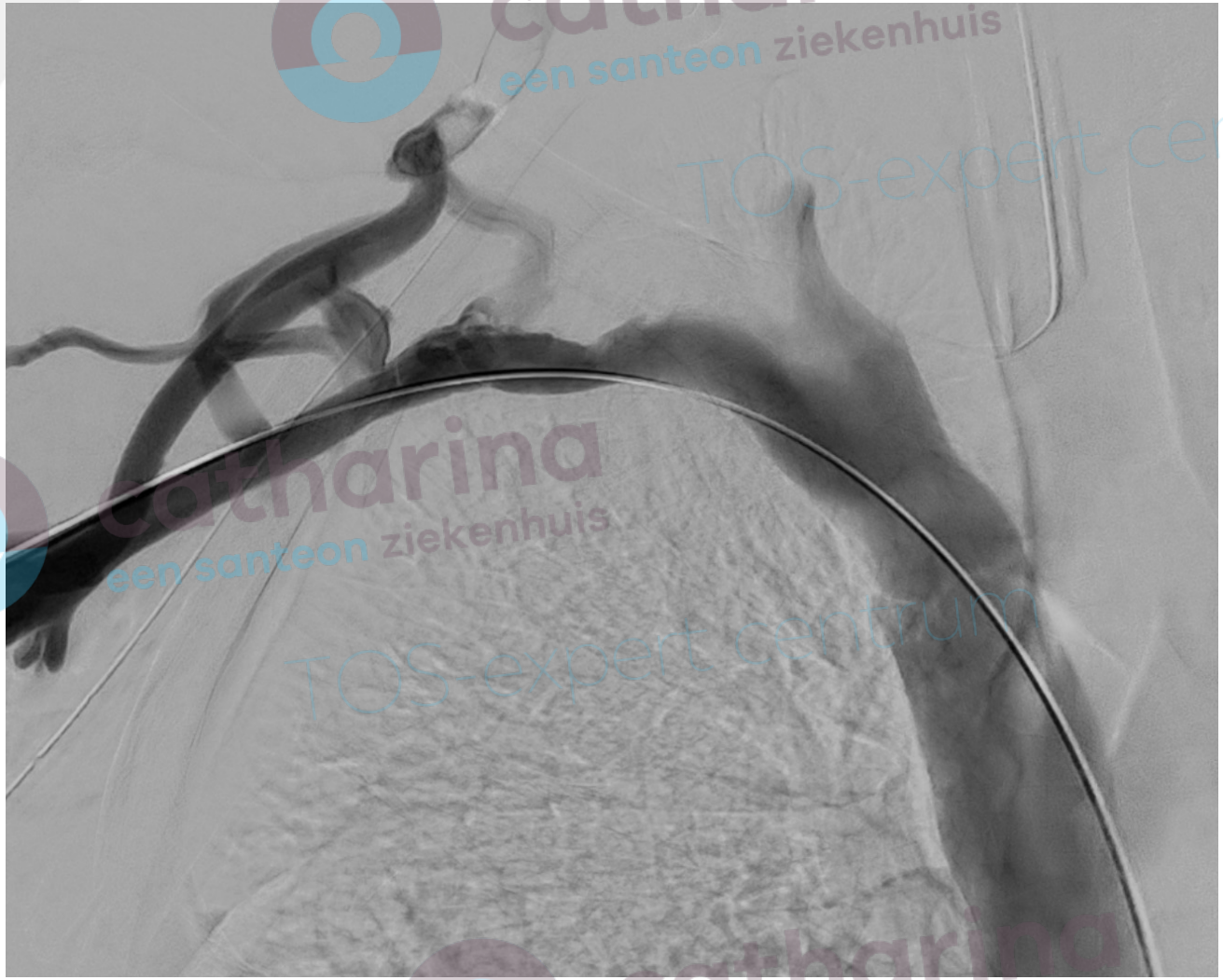

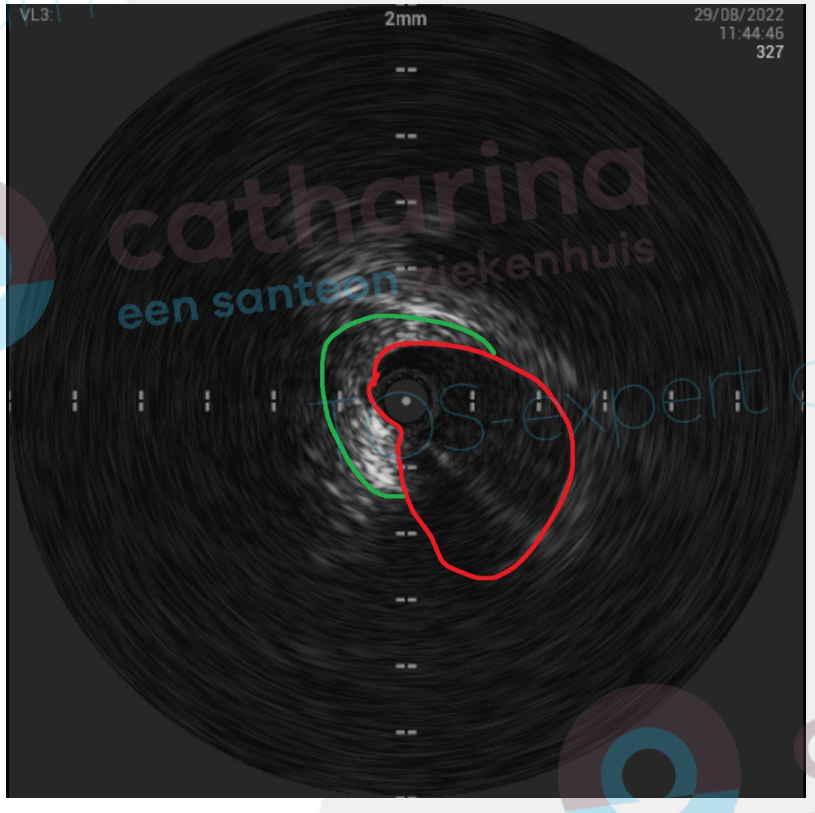

Stents

ARTICLE IN PRESS

Eur J Vasc Endovasc Surg (xxxx) xxx, xxx

Medium Term Outcomes of Deep Venous Stenting in the Management of Venous Thoracic Outlet Syndrome

Madeleine de Boer [a,*], Timothy Shiraev [a], Prakash Saha [b], Steven Dubenec [a]

[a] Department of Vascular Surgery, Royal Prince Alfred Hospital, Camperdown, NSW 2050, Australia
[b] Academic Department of Surgery, School of Cardiovascular Medicine & Sciences, British Heart Foundation of Research Excellence, King's College London, London, UK

Conclusion

The data from this study suggests that upper limb deep venous stenting as an adjunct to surgical decompression is effective in the management of vTOS. The promising midterm patency rates suggest that the traditional aversion to their use may need to be revised. Stenting after first rib resection to address residual stenotic lesions can lead to a reduction in ongoing symptoms, which, in turn, decreases the morbidity associated with vTOS. Ongoing surveillance is required to assess long term patency rates, and further studies with larger cohort numbers are required to confirm categorically these early findings.

Remodelering v. subclavia

- Man 26 jaar
- 13-07-2021 CTV + echo: verdenking v. subclvia trombose rechts
- 14-07-2021 PTA en trombosuctie v. axillaris + v. subclavia rechts, 16-07 trombolyse v. subclavia ivm resttrombus
- 06-08-2021 recidief trombosering, waarvoor nieuwe PTA en trombolyse
- Doorverwezen CZE

Remodelering v. subclavia

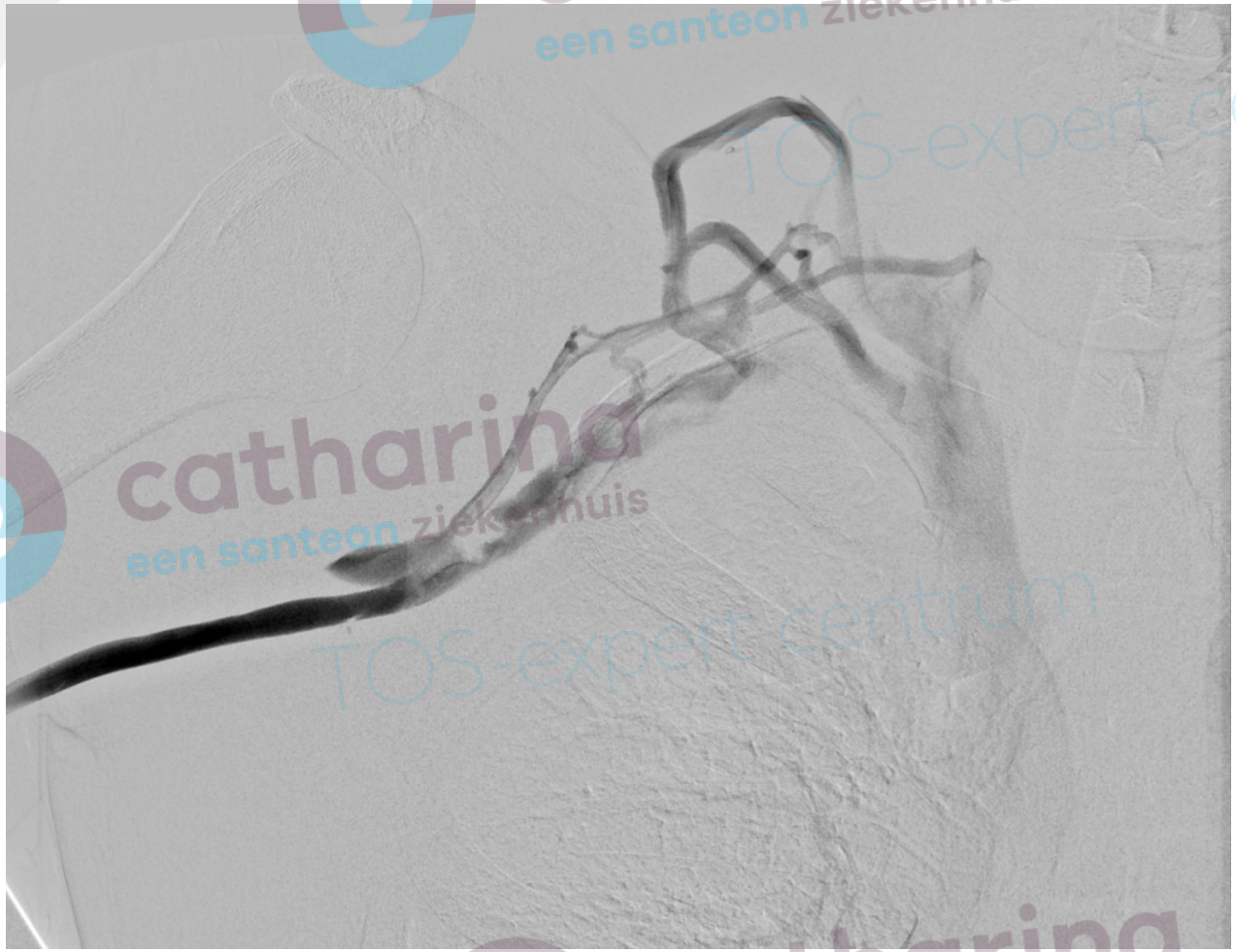

Flebografie elders

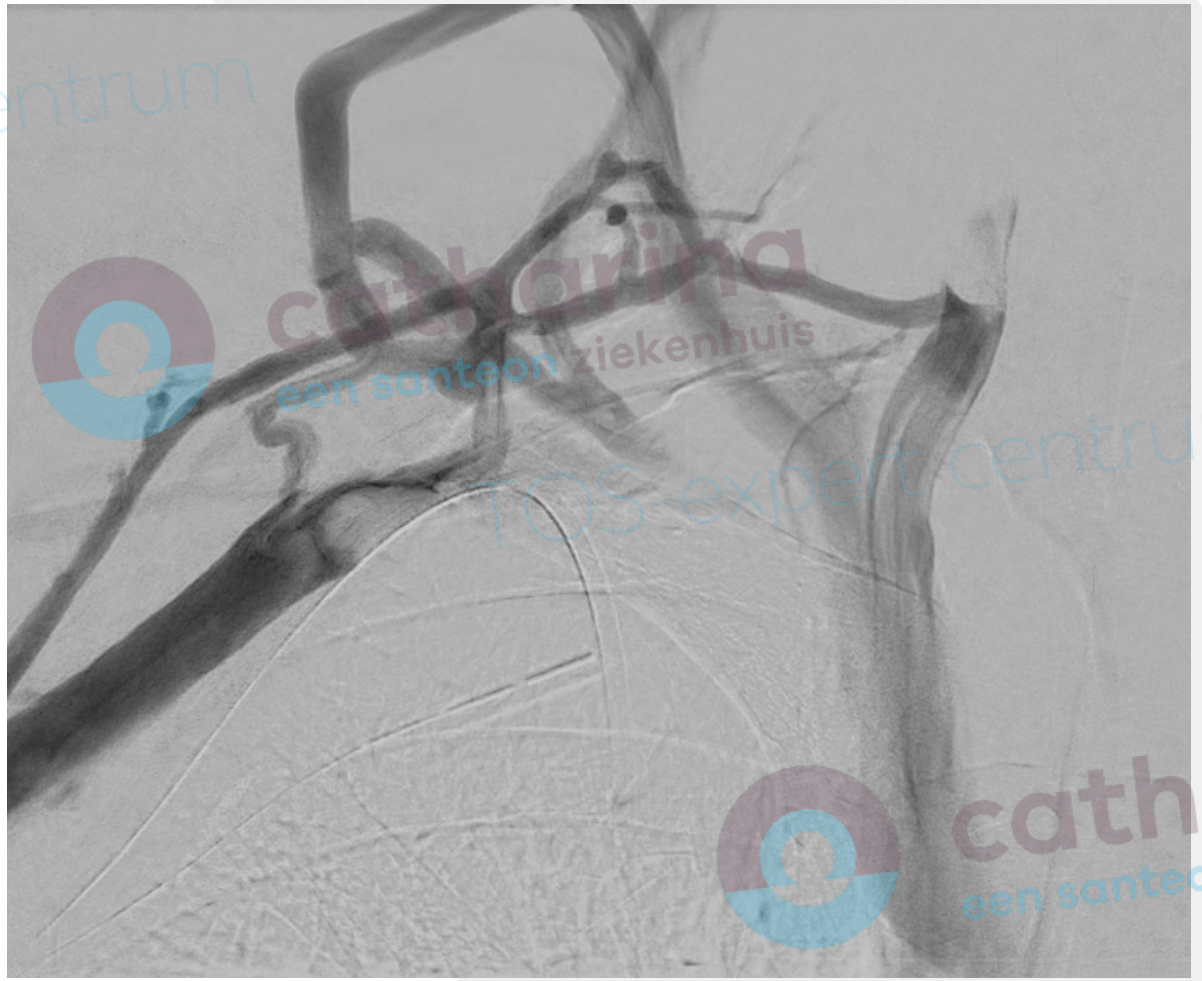

Flebografie postTOD

Remodelering v. subclavia

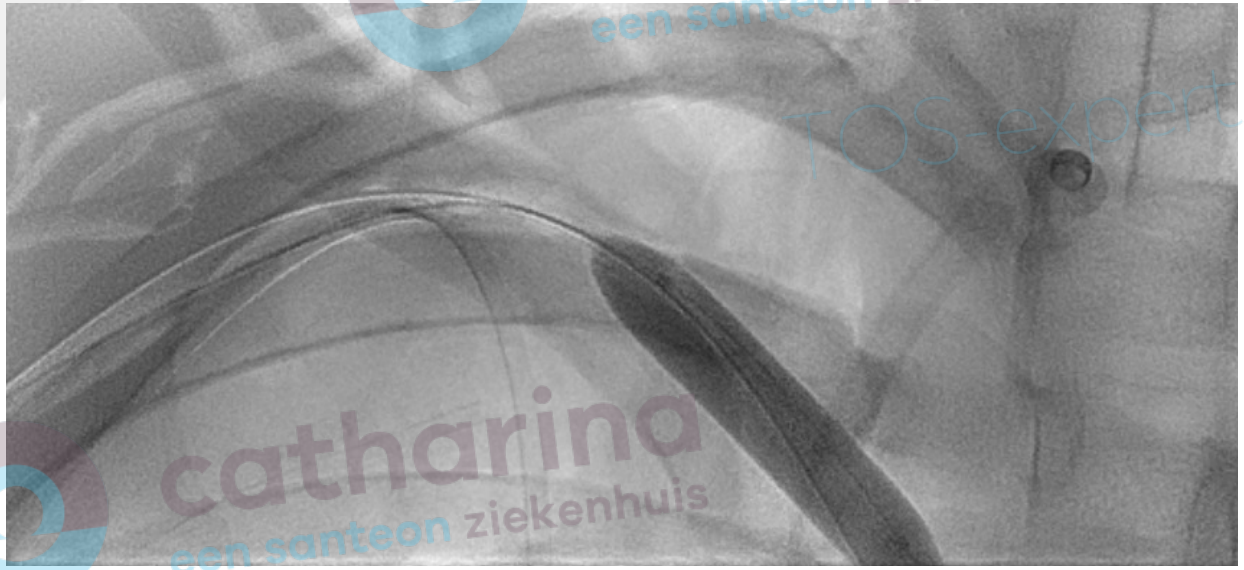

PTA direct postTOD

Flebografie postTOD en postPTA

Remodelering v. subclavia

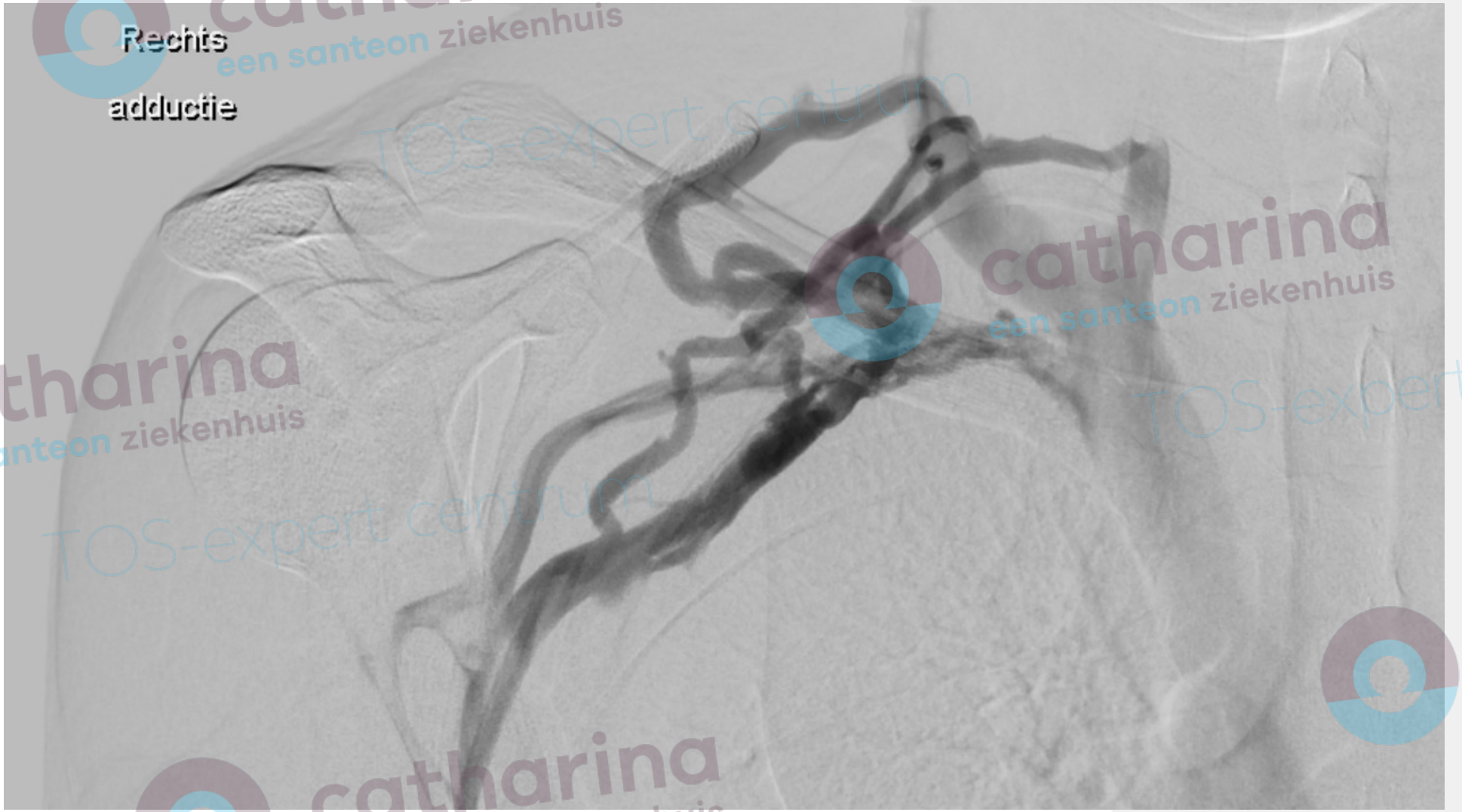

4 houdingen flebografie 3 maanden na TOD en PTA

Remodelering v. subclavia

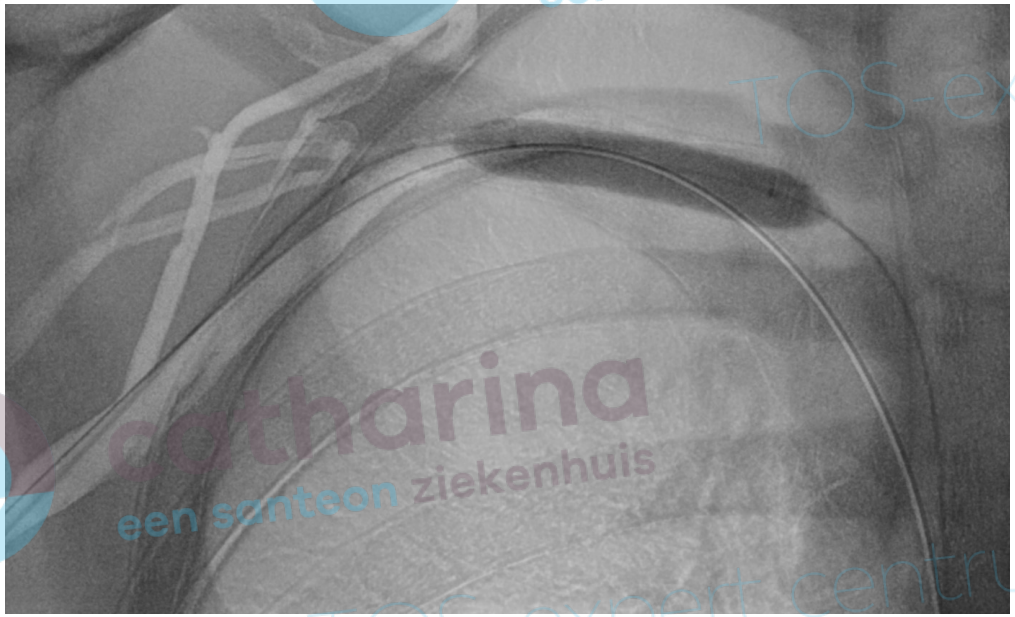

PMI en rePTA aansluitend aan flebografie

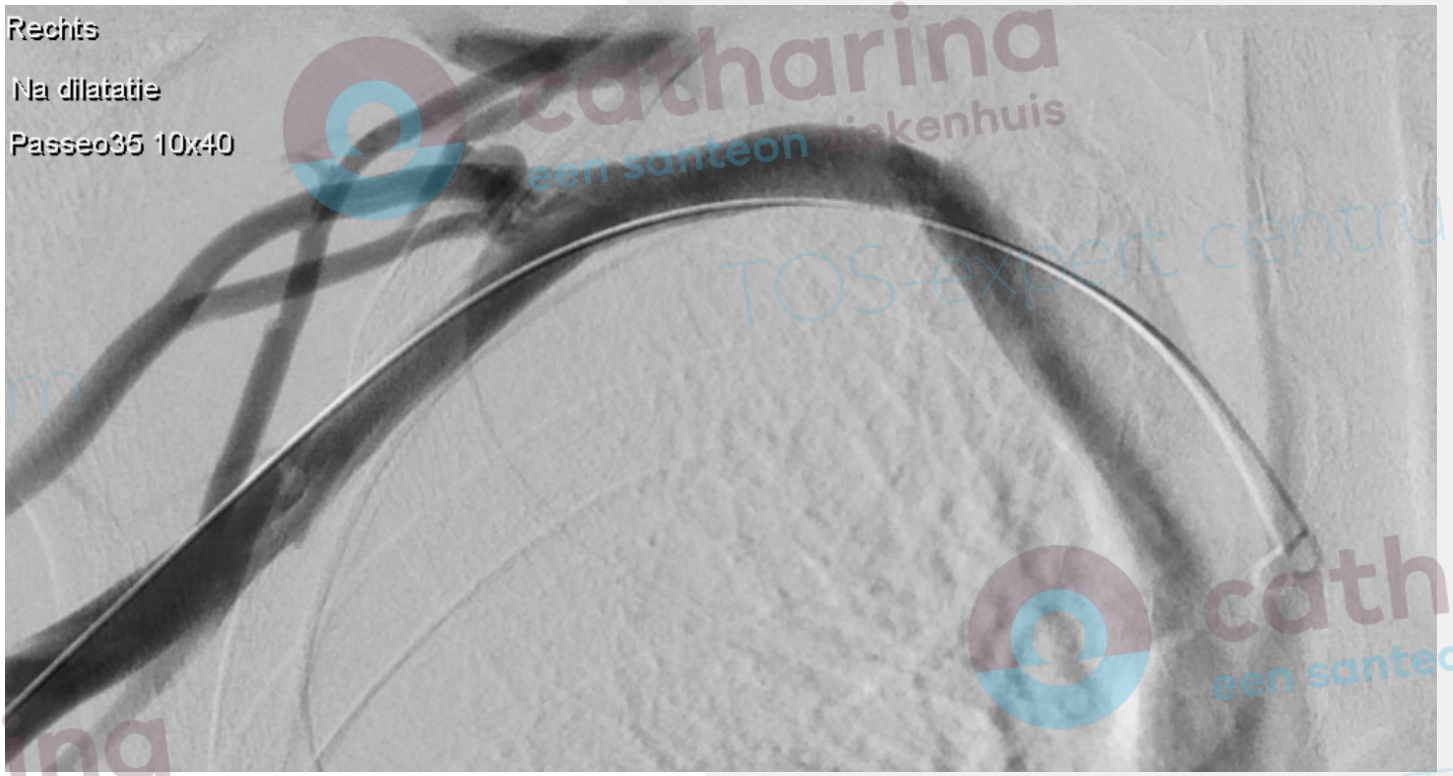

Flebografie postPTA

Remodelering v. subclavia

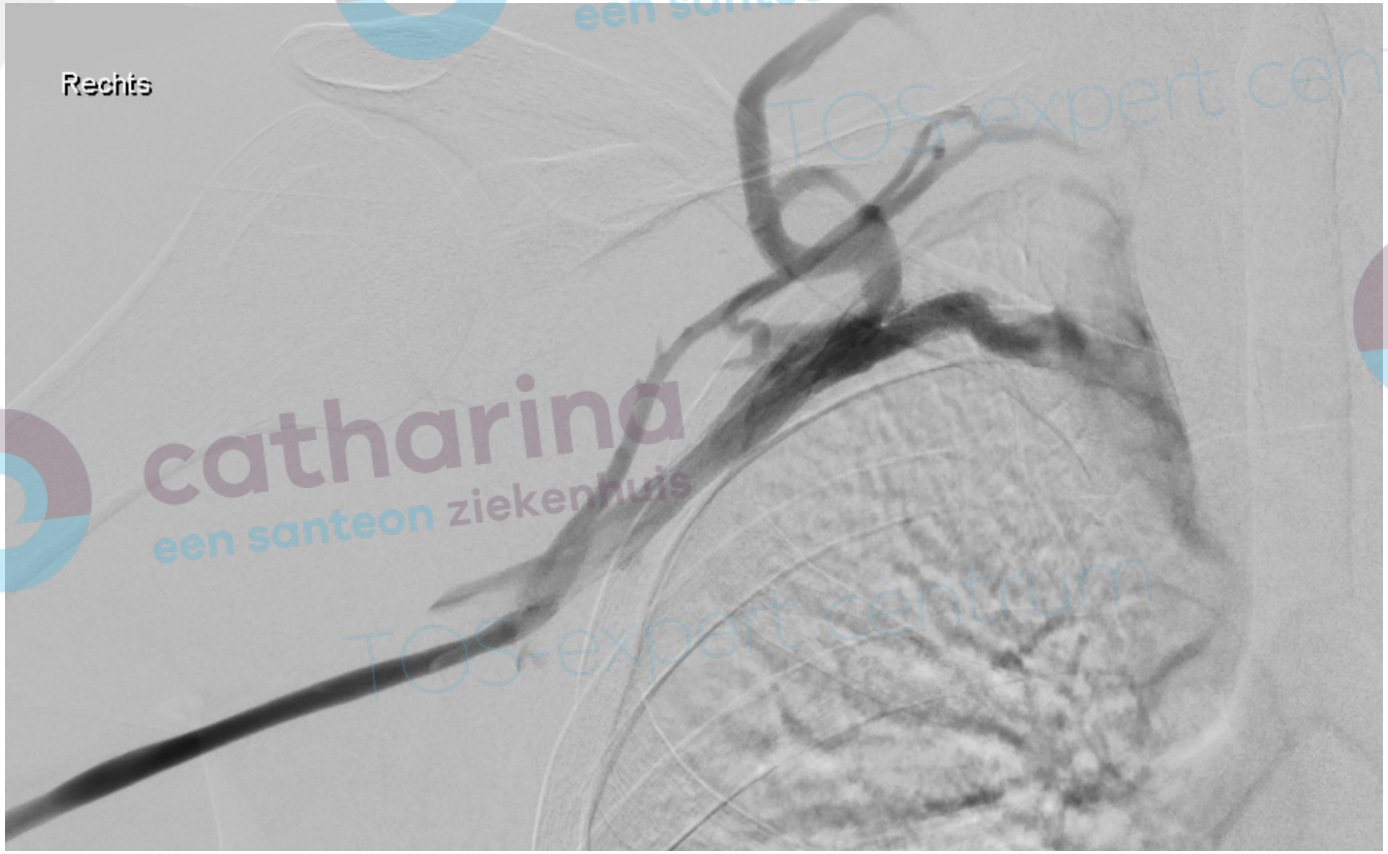

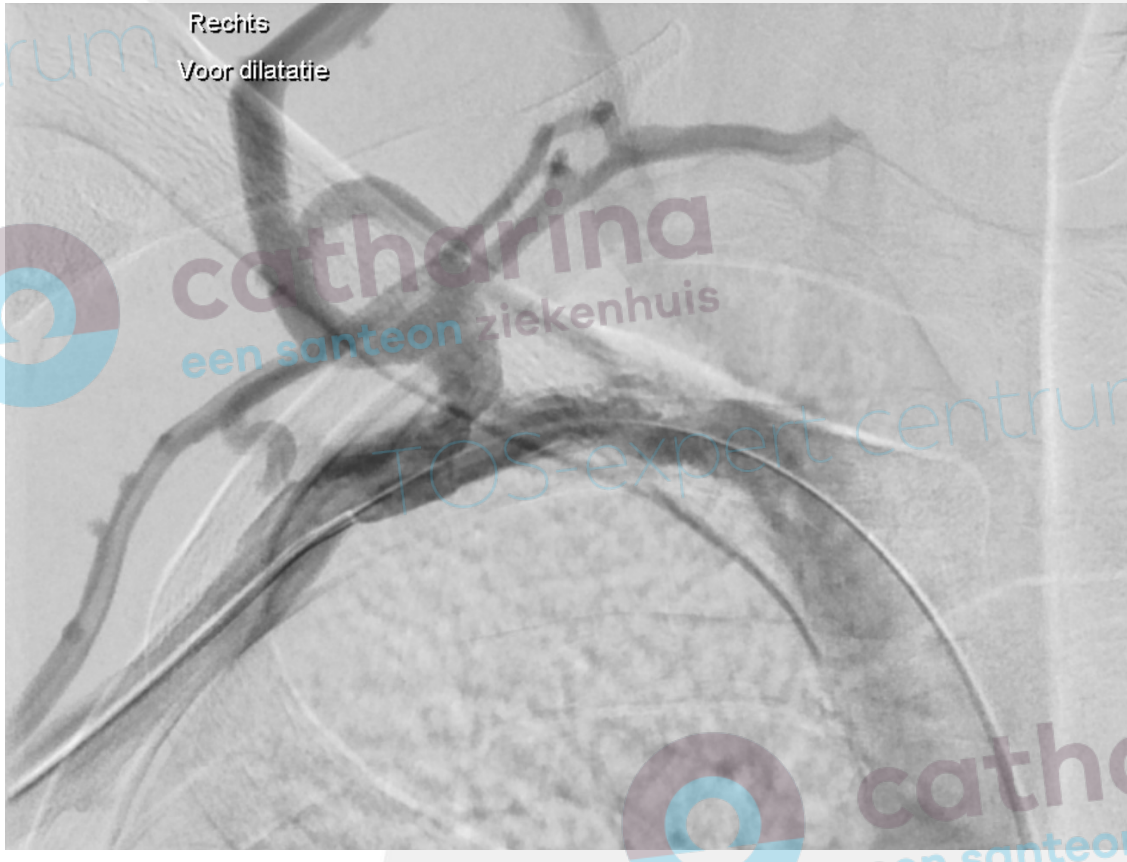

flebografie 7 maanden na TOD en PTA

Remodelering v. subclavia

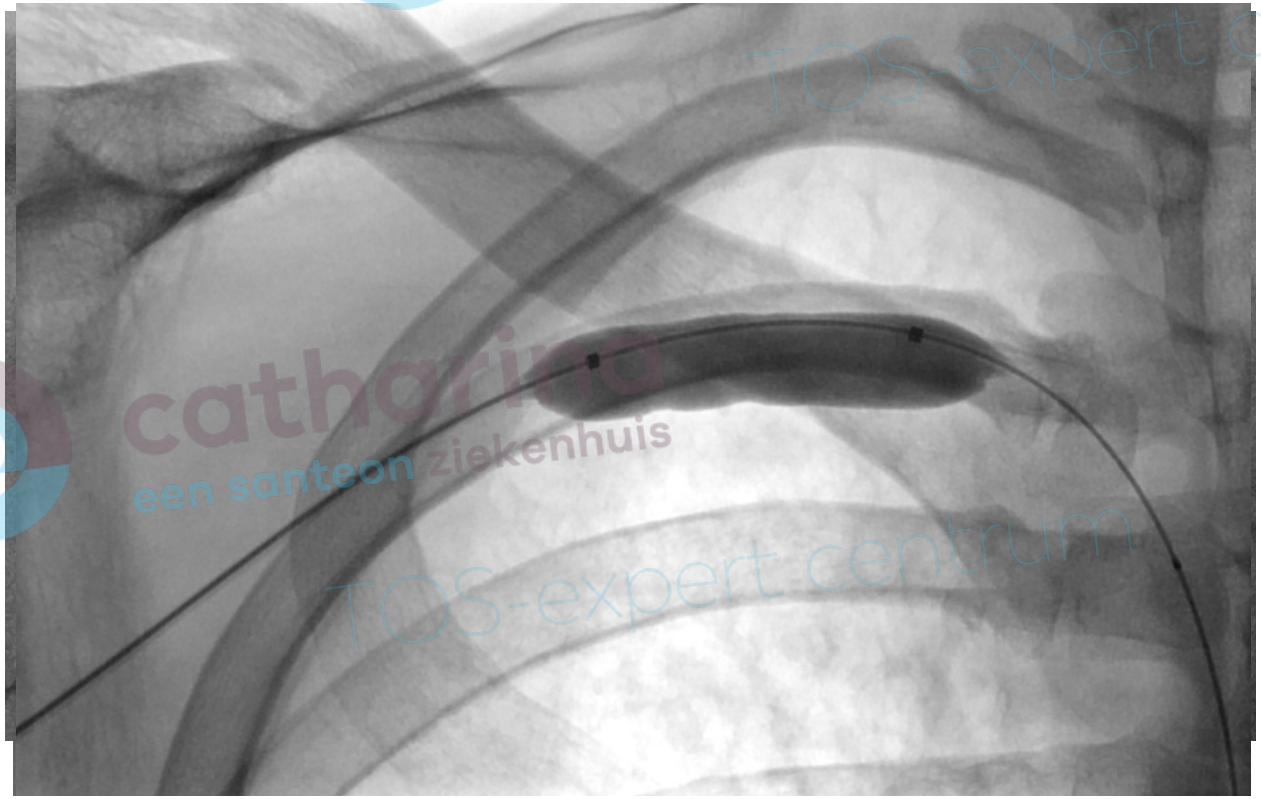

re-rePTA 7 maanden na TOD

Flebografie post re-rePTA

Remodelering v. subclavia

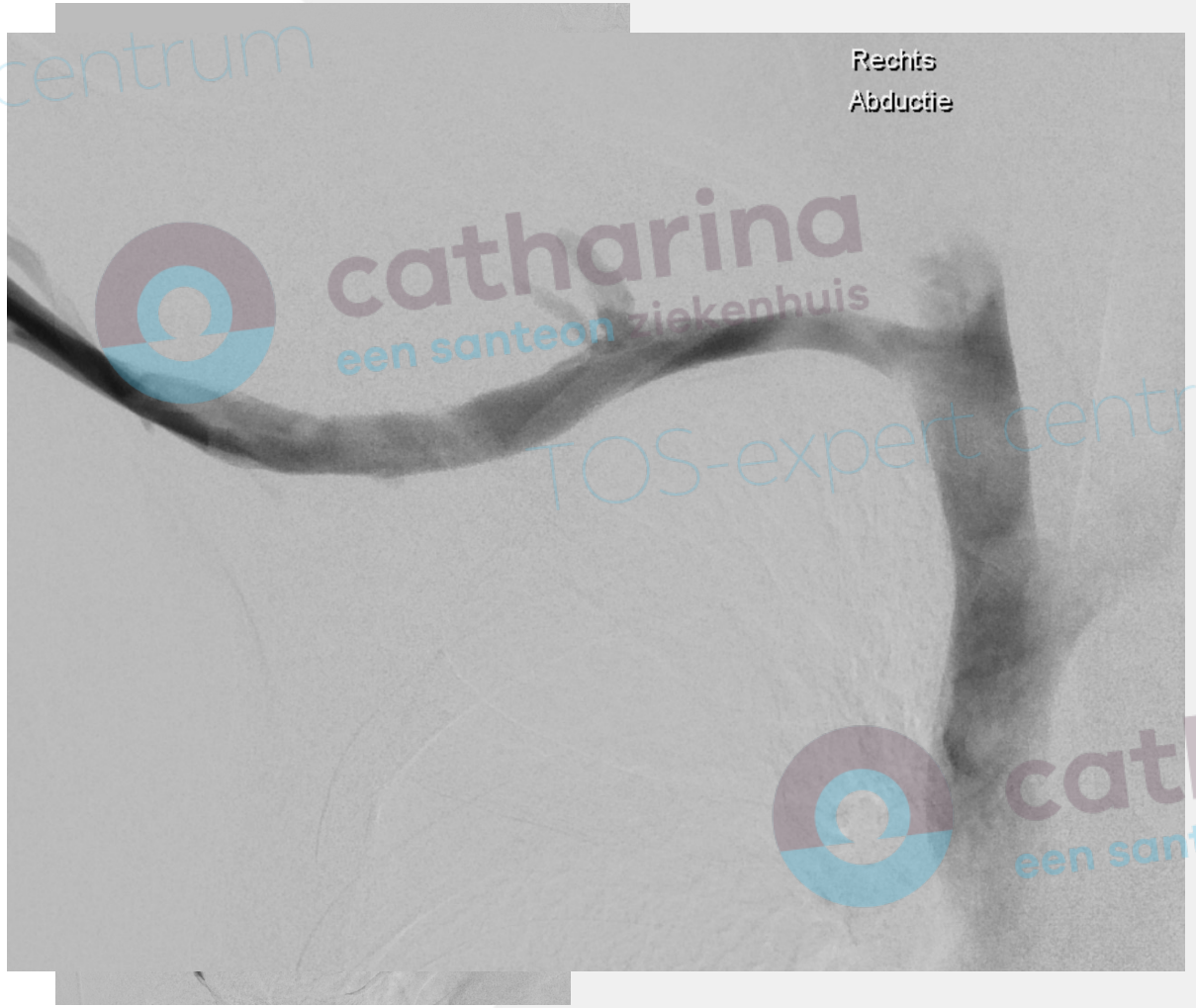

4 houdingen flebografie 13 maanden na TOD en 6 maanden na re-rePTA

Take home messages

- “Een trombose-arm bij jonge patiënten is een veneuze TOS tot het tegendeel bewezen is!”
- Diagnostiek bij voorkeur middels flebografie.
- Proefrekanalisatie bij chronische vTOS bepaalt behandelstrategie
- PMI mogelijk goedkoop en makkelijk alternatief voor een IVUS
- Stents vermijden bij deze jonge populatie, mede gezien het remodelerend vermogen van de vena subclavia